

# Safety Profile of *Pistacia lentiscus* powder and tears in rat

Farzana Sadaf\*, Sidra Siddiqui and Sarah Jameel Khan

Department of Pharmaceutics, Faculty of Pharmacy, Hamdard University, Karachi, Pakistan

**Abstract:** *Pistacia lentiscus* L (PL) is commonly known as gum mastic. Its powder and tears are widely used in herbal/medicinal item, cosmetics and food supplements. The oil and gum resin of (PL) are anticipated to be consuming with other pharmacological agents in order to avoid any drug- drug interaction. The study was design to evaluate the sub-acute toxicity of gum mastic powder (GMP) and gum mastic tears (GMT) at the dose of 0.2857g/kg for a duration of 14 days. On 14<sup>th</sup> day of experiment, different biochemical test was performed on animal blood sample and then sacrificed for histopathological analysis of heart, liver and kidney and spleen. There were no significant differences in the gross and histopathology changes in vital organs like heart, liver and kidney and spleen tissues at the dose of 0.2857g/kg of gum mastic tears and powder and their corresponding control. The results indicate that both GMP and GMT can be used as cardio-protective and in gout treatment. It was concluded that use of gum mastic tears and powdered was found to be safe and consequently use in the pharmaceutical and cosmetic industries.

**Keywords:** *Pistacia lentiscus*, sub-acute toxicity, gum mastic powder (GMP), gum mastic tears (GMT).

## INTRODUCTION

Globally, traditional medicine is the backbone of health care for treating disease. Despite these worldwide applications of traditional medicine, lots of plant products have not been studied because of their hazardous effect in animal or human being (Parra *et al.* 2001).

*Pistacia lentiscus* (PL) commonly is a resin from mastic tree. It is an evergreen shrub belongs to the Pistacio family. The word mastic is derived either from the Greek verb mastichein ("to gnash the teeth") or massein ("to chew"). It is the native plant of Mediterranean and Middle Eastern region. *Pistacia lentiscus* (PL) has been used in various societies for centuries in cooking, community and formal purposes as well as gain interest as medicinal entity also. PL is rich in monoterpenes and sesquiterpenes accounts for smelling and flavoring of the plant. The essential oil of *Pistacia lentiscus* and its leaves, bark and fruits extracts are widely used for managing disease condition. Water extract of PL possess significant activity against gastrointestinal, urinary, hepatic, neurological and pulmonary diseases

(Milia *et al.* 2021). PL has been one of most used traditional plant in treating jaundice (Janakat and Al-Merie 2002). It also possesses antimicrobial, antioxidant, hypotensive, cardiac and hypoglycemic activity and treat coughs, sore throats and eczema; (Saiah *et al.* 2016) (Missoun *et al.* 2017); (Giner-Larza *et al.* 2001); (Trabelsi *et al.* 2012). This plant is also called lentisk. The aerial portion is diuretic and aids in the treatment of hypertension. Additionally, it functions as an antibacterial, antiproliferative, and antioxidant agent. Scabies and rheumatism have both been treated with success using this method. Its various components include resin, essential oils, Gallic acid, anthocyanin, flavonol glycosides, and

triterpenoids, tocopherol, and arabinogalactan proteins, among other chemical substances with significant medical use. Lentisk's health-promoting qualities have also been linked to the presence of other biologically active substances (BACs), like phenolic compounds. (Sehaki *et al.* 2023) Plant has shown the antibacterial and apoptosis modulating activities (Gortzi *et al.* 2022); (Spyridopoulou *et al.* 2017). The aqueous leaves extract of *Pistacia lentiscus* exhibited antioxidant and hepatoprotective potential (Ljubuncic *et al.* 2005). The resin of *Pistacia lentiscus* shows antifungal properties (Duru *et al.* 2003). Gum mastic extracts were used against *Helicobacter pylori* (Paraschos *et al.* 2007). Despite its historical and multiple uses, there was no data on the safety profile of mastic gum and tears. The current study was designed to assess the safety profile, a well as aiming to focus on the sub- acute toxicity of the resin and powder of plant (*Pistacia lentiscus*).

## MATERIALS AND METHODS

### Drug

Gum Mastic Powder and Tears is manageable from Hamdard Laboratories (Waqf) Pakistan. The powder is not finely crushed because it is gummy in nature and when dissolved in distilled water, particles stuck on spatula. Tears are off- white crystals. Both powder and tears are partly soluble in 10% tween 80 gives heterogeneous solution. Hematoxylin is purchased from BDH Chemicals Ltd Poole England and Eosin from E. Merck (H & E).

### Animals

Male and female Sprague Dawley rats weighing between (235-370g) were used in the study. They are purchased from animal house of Dr. HMI Institute of Pharmacology and Herbal Sciences. Initially they are kept in individual cages under controlled conditions of light (12h with alternate day and night cycles) and temperature (22±0.5°C)

\*Corresponding author: e-mail: Farzana.Sadaf@hamdard.edu.pk

with food and tap water *ad libitum* freely accessible during the experiment. (Council 2010)

### **Experimental protocol**

#### **(i) Safety evaluation studies of gum mastic powder and tears**

##### **(a) Sub-acute toxicity on rats**

This study was performed according to the Organization of Economic Co-Operation and Development (OECD) guideline 407 for testing of chemicals (OECD, 2008). Thirty healthy Sprague Dawley rats were classified into three groups (n=10 each). The control group administered 10% tween 80 orally control as a vehicle at the same volume whereas the experimental groups treated by oral feeding tube with gum mastic powder (0.2857g/kg i.e., 10 times higher dose) and gum mastic tears (0.2857g/kg i.e., 10 times higher dose) respectively once daily during continuous 14 days. Each animal was weighed daily before the drug administrations. At the interval between 11.00 12.00 a.m. drug administration was done to avoid circadian interference. Animals should be observed for 2h after dose administration, for any alteration in behavior or apparent actions (WHO, 2000).

##### **(b) Biochemical study on rats**

All animals were given anesthetic by inhalation at the completion of study. Animals were anaesthetized at least 24 hours after the last dosage of treatment. After that samples of blood were drawn and centrifuged by centrifuging machine (Model 80- 2, No. 02561, Changzhou Guohua Electric Appliance CO. Ltd, China) at a rate of 1500-2000 rpm for 15 minutes. The kits were purchased from Diagnostica Merck (Germany). The serum Total Cholesterol, HDL, LDL, CHOL/HDL Ratio, Triglyceride,  $\gamma$  GT, SGPT, Alkaline Phosphatase, Urea, Uric acid, Creatinine, Glucose was examined by spectrophotometer (Hitachi U- 2000) on the similar day.

##### **(c) Autopsy**

Various organs like spleen, kidney, liver and heart were removed from the study animals, blotted and immediately weighed on an electronic balance (Sartorius BP- 211- D).

##### **(d) Histopathological study**

After the blood collection immediately kidney, liver, spleen and heart were taken in small pieces and then fixation, dehydration, cleaning and embedding done in 10% neutral formalin, graded (80-100%) alcohol, xylene and in paraffin wax. 4-5 $\mu$ m thick sections were prepared by Leica RM 2145- Rotatory Microtome, then deparaffinated in xylene, passed through 80% to 100% alcohol and stained with Hematoxylin and Eosin (H & E). The tissues were examined and photographed through Nikon's Advanced Research Microscope OPTIPHOT Model X2T-21E assembled with Nikon's Microphotography system; Model UFX-DX-35 and phase contrast N plan for the evaluation and comparing structural

changes within different groups of rats marked as control and treated.

### **Ethical approval**

Handling of laboratory animals was approved by Hamdard University Ethical Review Board HU-ERB (Ref No. AEC-16-02).

### **STATISTICAL ANALYSIS**

By using SPSS software version 20.0 differences between means of gum mastic powder (GMP) and tears (GMT) were compared with control value. Values are presented as mean  $\pm$  SEM and scrutinized by student's t-test. The result was significantly measured at *p*-value <0.05.

### **RESULTS**

#### **(i) Toxicological study of GMP and GMT on rats**

Rats treated with GMP and GMT (0.285g/kg which is 10 times human) did not show any mortality. None of no any sign of toxicity observed in any animal. Non- significant rise in the weight of animals treated with GMP and GMT was observed in comparison to the control group (table 1).

#### **ii) Autopsy**

No gross change in any organ (heart, right kidney, left kidney and spleen) were observed, only the dry weight of liver which is significantly increased as compared to control group (*p*<0.05) as shown in table 1.

#### **(iii) Biochemical study of GMP and GMT on rats**

The effects of sub-acute administration of GMP and GMT on biochemical parameters are presented in table 1. There is a significant decrease in serum total cholesterol (*p*<0.05, *p*<0.025) when treated with GMP and GMT respectively.

Non- significant decrease in serum triglycerides was observed treated with GMP but a significant (*p*<0.05) increase was seen when treated with GMT (10 times higher than human dose). The serum HDL was non-significantly decreased in GMP and increased in GMT. A similar dose of GMP (0.258g/kg) non significantly decreases the Cholesterol/ HDL Ratio but significantly decreases (*p*<0.05) the cholesterol/ HDL Ratio when treated with GMT.

The kidney function markers like urea, uric acid and creatinine exhibit no significant changes. Likewise, no significant differences seen in the liver enzymes like alanine aminotransferase (ALT) and alkaline phosphatase (ALP). However, Gamma-glutamyl transferase ( $\gamma$  GT) is non-significantly increased in GMP at the dose of 0.285g/kg but there is a significant increased (*p*<0.05) when treated with GMT at the dose of 0.285g/kg. Moreover, no relevant changes were found in serum glucose level (table 1).

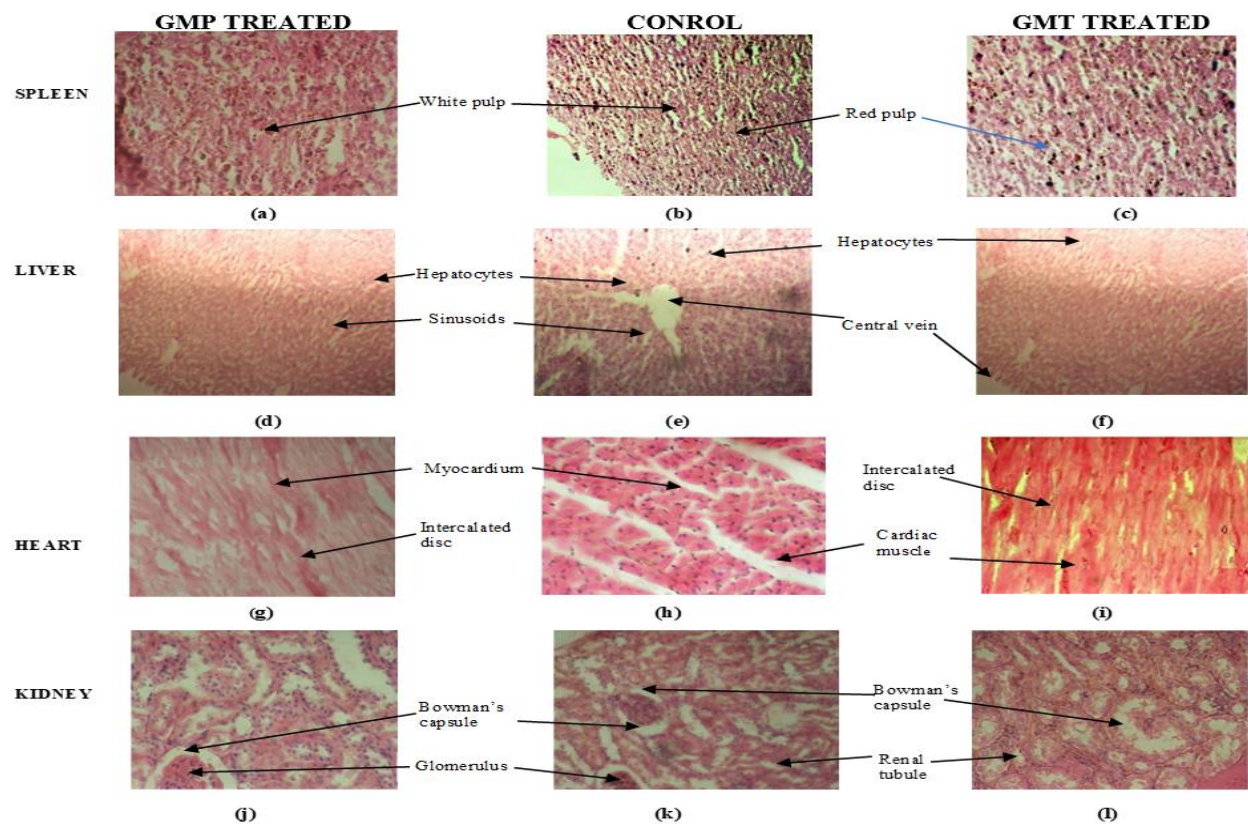
**Table 1:** Toxicological Study of GMP and GMT after fourteen days treatment in rats

Parameters	10 % Tween 80 control	GMP (0.285 g/kg)	GMT (0.285 g/kg)
<i>Route of Administration</i>	p.o	p.o	p.o
Body weight (g)	278.52±17.73	288.89±16.99	283.09±18.40
Weight of liver (g)	7.784±0.257	7.797±0.260	8.64±0.360*
Weight of heart (g)	0.96±0.051	1.004±0.058	0.988±0.0526
Weight of Kidney (R) (g)	0.816±0.044	0.824±0.037	0.882±0.060
Weight of Kidney (L) (g)	0.8126±0.045	0.839±0.042	0.881±0.048
Weight of Spleen (g)	0.671±0.034	0.649±0.035	0.713±0.109
Mortality	NIL	NIL	NIL
Toxic effect	NIL	NIL	NIL

Values represents mean ± SEM in control (saline) and orally treated (GMP and GMT 0.285g/kg) rats (n = 6), \*p<0.05.

**Table 2:** Biochemical Study of GMP and GMT after fourteen days treatment in rats

Biochemicals (mg/dl)	Control	Gum Mastic Powder	Gum Mastic Tears
Cholesterol	148.66±4.06	136.59±4.25*	137.70±1.70**
Triglycerides	242.99±6.22	232.03±4.37	219.70±8.81*
HDL	69.58±1.93	67.28±1.78	72.59±2.94
LDL	30.480±4.44	22.892±3.63	21.166±3.74
CHOL/HDL Ratio	2.148±0.09	2.033±0.058	1.909±0.07*
Urea	11.33±32.10	30.80±11.09	36.23±14.53
Creatinine	1.82±1.59	1.15±1.31	0.82±0.26
Uric acid	5.03±0.17	5.28±0.14	5.50±0.27
SGPT	312.62±11.35	331.08±5.90	331.07±10.46
Gamma GT	249.47±9.76	269.65±22.40	280.79±14.31*
AlkPO <sub>4</sub>	1044.97±25.91	1045.82±27.51	1063.51±17.56
Glucose	102.46±3.16	101.92±7.00	103.90±4.78

**Fig. 1:** Histopathological profile of spleen, liver, heart and kidney of GMP, control and GMT treated rat.

**(iv) Histopathological study**

Slides of rat spleen treated with GMP and GMT with 0.285g/kg was seen normal revealing cylindrical sheath of periarterial lymphatic sheath (PALS) of white pulp surrounded by central artery and a dense vascular red pulp as compared to spleen of rats of vehicle group (fig. 1a, b, c).

It was clearly observed that the slides of GMP and GMT treated liver with central vein and hepatic sinusoids are arranged with endothelial and Kupffer cells similar to that of control group (fig. 1d, e, f). The liver cells seemed regular form and dimensions and no vacuoles were examined in their cytoplasm.

Heart muscles displayed cross-striations and separate muscle fiber display a central nucleus. A distinctive characteristic of the intercalated disks was also revealed normal. Intercalated disc representing intracellular junction between two myocardia (fig. 1g, h, i).

Histological examination of kidney of both control and GMP and GMT treated animals showed normal integral glomerular and tubular arrangement (fig. 1j, k, l). Normal appearance of the capillary tufts and mass of the Bowman's space also seen.

**DISCUSSION**

The use of herbal plants in cosmetics and toiletry products has gaining interest. The best thing about the herbal cosmetics is that it consists of pure herbs which are free of side effects and don't harm the human body (Gediya *et al.* 2011).

The objective of this research analysis was to determine the sub-acute toxicity of GMP and GMT in rats. Toxicity and mortality signs were not observed at the dose of 0.2587g/kg. Results showed no apparent changes in heart, kidney and spleen and their dried weight when subjected to tissue analysis while the weight of liver was significantly increased when treated with GMT as compared to its respective control group.

The findings of the current examination prove the believe of traditional practitioners. They emphasize that herbs like GMT decrease total cholesterol level, triglycerides and cholesterol/HDL ratio. On the other hand, GMP decreases total body cholesterol, whereas other lipid parameters like triglycerides was non-significantly decreased. So, it is concluded that at the above-mentioned dose GMT possess more significant anti-hypercholesterolemic activity. The presence of chemical constituents like terpenoids (monoterpenoids and sesquiterpenoids) attributed to this therapeutic activity (Azaizeh *et al.* 2013);(Middleton and Kok-Pheng 1982) Gamma glutamyl transferase ( $\gamma$  GT) in the liver profile was significantly increased in rats treated

with GMT but non- significant in GMP at the same dose. This moderate rise in  $\gamma$  GT is observed during acute hepatitis, cirrhosis and hepatic steatosis (Krishnamurthy 2013); (Fujii *et al.* 2020). Ascites evident with increase size of liver when treated with GMT eliciting hepatomegaly. Though, the difference in GGT level is developed at the dose of 0.2587g/kg that is 10 times more than human dose however, these findings may be absent in prescribed dose.

The histopathological study shows no significant change in cell morphology of kidney, liver, heart and spleen.

**CONCLUSION**

The detailed analysis of sub-acute toxicity of *Pistacia lentiscus* in rats showed no sign of lethality and histopathological toxicity. However, there is some variation in serum biochemical parameters which may be ambiguous at prescribed dose. Thus, it seems that it may be used as an ingredient in compound for human consumption.

**REFERENCES**

Azaizeh H, F Halahleh, N Abbas, A Markovics, H Muklada, E Ungar and S Landau (2013). Polyphenols from *Pistacia lentiscus* and *Phillyrea latifolia* impair the exsheathment of gastro-intestinal nematode larvae. *Veterinary parasitology* **191**(1-2): 44-50.

Council N (2010). Guide for the care and use of laboratory animals (No. 86). US Department of Health and Human Services. Public Health Service, National Institutes of Health.

Duru M, A Cakir, S Kordali, H Zengin, M Harmandar, S Izumi and T Hirata (2003). Chemical composition and antifungal properties of essential oils of three *Pistacia* species. *Fitoterapia.*, **74**(1): 170-176.

Fujii H, T Ko, T Fukuma, T Kadono, K Asaeda, R Kobayashi, T Nakano, Y Nakatsugawa, S Yamada and T Nishimura (2020). Frequently abnormal serum gamma-glutamyl transferase activity is associated with future development of fatty liver: A retrospective cohort study. *BMC gastroenterology.*, **20**(1): 1-9.

Gediya SK, RB Mistry, UK Patel, M Blessy and HN Jain (2011). Herbal plants: Used as a cosmetics. *J Nat Prod Plant Resour.*, **1**(1): 24-32.

Giner-Larza EM, S Manez, MC Recio, RM Giner, JM Prieto, M Cerda-Nicolas and JL Ros (2001). Oleanonic acid, a 3-oxotriterpene from *Pistacia*, inhibits leukotriene synthesis and has anti-inflammatory activity. *Eur. J. Pharmacol.*, **428**(1): 137-143.

Gortzi O, M Rovoli, K Katsoulis, K Graikou, DA Karagkini, D Stagos, D Kouretas, J Tsaknis and I Chinou (2022). Study of stability, cytotoxic and antimicrobial activity of chios mastic gum fractions (neutral, acidic) after encapsulation in liposomes. *Foods.*, **11**(3): 271.

- Janakat S and H Al-Merie (2002). Evaluation of hepatoprotective effect of Pistacia lentiscus, Phillyrea latifolia and Nicotiana glauca. *J. Ethnopharmacol.*, **83**(1-2): 135-138.
- Krishnamurthy H (2013). The Serum Gamma Glutamyl Transpeptidase-A Non invasive Diagnostic Bio Marker of Chronic Anicteric Non Alcoholic Liver Diseases. *J. Clin. Diagnostic Res: JCDR.*, **7**(4): 691.
- Ljubuncic P, H Song, U Cogan, H Azaizeh and A Bomzon (2005). The effects of aqueous extracts prepared from the leaves of Pistacia lentiscus in experimental liver disease. *J. Ethnopharmacol.*, **100**(1-2): 198-204.
- Middleton B and H Kok-Pheng (1982). Inhibition of hepatic S-3-hydroxy-3-methylglutaryl-CoA reductase and in vivo rates of lipogenesis by a mixture of pure cyclic monoterpenes. *Biochem. Pharmacol.*, **31**(18): 2897-2901.
- Milia E, S Bullitta, G Mastandrea, B Szotáková, A Schoubben, L Langhansová, M Quartu, A Bortone and S Eick (2021). Pistacia lentiscus: From Phytopharmacology to Scientific Explanations on Its Anti-Inflammatory and Antimicrobial Capacity.
- Missoun F, F Bouabedelli, E Benhamimed, A Baghdad and N Djebli (2017). "Phytochemical study and antibacterial activity of different extracts of Pistacia lentiscus L collected from Dahra Region West of Algeria. *J. Fundam Appl Sci.*, **9**(2): 669-684.
- Paraschos S, P Magiatis, S Mitakou, K Petraki, A Kalliaropoulos, P Maragkoudakis, A Mentis, D Sgouras and AL Skaltsounis (2007). *In vitro* and *in vivo* activities of Chios mastic gum extracts and constituents against Helicobacter pylori. *Antimicrob. Agents Chemother.*, **51**(2): 551-559.
- Parra AL, RS Yhebra, IG Sardiñas and LI Buela (2001). Comparative study of the assay of Artemia salina L. and the estimate of the medium lethal dose (LD50 value) in mice, to determine oral acute toxicity of plant extracts. *Phytomedicine*, **8**(5): 395-400.
- Saiah H, R Allem and F Kebir (2016). Antioxidant and antibacterial activities of six Algerian medicinal plants. *Int. J. Pharm. Pharm. Sci.*, **8**: 367-374.
- Sehaki C, N Jullian, F Ayati, F Fernane and E Gontier (2023). A Review of Pistacia lentiscus Polyphenols: Chemical Diversity and Pharmacological Activities. *Plants.*, **12**(2): 279.
- Spyridopoulou K, A Tiptiri-Kourpeti, E Lampri, E Fitsiou, S Vasileiadis, M Vamvakias, H Bardouki, A Goussia, V Malamou-Mitsi and MI Panayiotidis (2017). Dietary mastic oil extracted from Pistacia lentiscus var. Chia suppresses tumor growth in experimental colon cancer models. *Sci. Rep.*, **7**(1): 3782.
- Trabelsi H, OA Cherif, F Sakouhi, P Villeneuve, J Renaud, N Barouh, S Boukhchina and P Mayer (2012). Total lipid content, fatty acids and 4-desmethylsterols accumulation in developing fruit of Pistacia lentiscus L. growing wild in Tunisia. *Food Chem.*, **131**(2): 434-44.