

Phytochemical analysis and antihyperglycemic activity of *Carissa grandiflora* leaves extract on streptozotocin-induced diabetic mice

Imran Waheed^{1,2}, Sayyeda Saba², Khurram Aamir¹, Maria², Madiha Javaid³, Hira Ijaz⁴, Farooq Saleem² and SulamanYaqub¹

¹Akhtar Saeed College of Pharmacy, Canal Campus, Lahore, Pakistan

²Faculty of Pharmacy, The University of Lahore, Lahore, Pakistan

³Punjab University College of Pharmacy, University of the Punjab, Lahore, Pakistan

⁴Department of Pharmaceutical Sciences, Pak-Austria Fachhochschule, Institute of Applied Science and Technology, Haripur, Khyber Pakhtunkhwa, Pakistan

Abstract: Diabetes mellitus (DM), a prevalent metabolic condition that impairs glucose metabolism, causes morbidity and hospitalization. Thus, there is need to establish novel therapeutics against DM. The current study examined the phytochemical analysis and antidiabetic effects of *Carissa grandiflora* leave extracts (CGLE) on streptozotocin (STZ)-induced DM in mice. CGLE (n-hexane, chloroform, ethanol) was extracted and phytochemically examined for primary and secondary metabolites. Fourier transformed infrared spectroscopy (FTIR) detected functional groups, while 2,2-diphenyl-1-picrylhydrazyl (DPPH) test assessed antioxidant capacity. Later, antidiabetic potential of CGLE extract was investigated *in vivo* in STZ induced diabetic mice. Phytochemical investigation revealed sugars, ketones, alkaloids, triterpenoids, and glycosides. FTIR indicated phenol, aldehyde, ketone, alkene, alkyne, alcohol, benzene ring and amines, while DPPH assay demonstrated antioxidant potential of extract. Oral CGLE treatment significantly improved body weight ($P<0.05$), polyphagia and polydipsia ($P<0.05$) and FBG ($P<0.001$). Moreover, CGLE extract reversed histopathological alterations in the pancreas, liver, and kidney of diabetic mice. These outcomes highlighted that *C. grandiflora* extract could be effective therapeutic approach against DM.

Keywords: *Carissa grandiflora*, diabetes mellitus, streptozotocin, antioxidant activity, histomorphology.

INTRODUCTION

Diabetes mellitus (DM) is a common metabolic disorder characterized by impairment in the metabolism of carbohydrates that leads to morbidity and hospitalization. The escalation in the global prevalence of DM seriously affects developed and developing states (Tareen and Tareen, 2017). A recent report by International Diabetes Federation (IDF) clearly indicated that 415 million individuals are diabetic and further predicted to be 642 million by the year 2040 (Sudhakar, 2021).

This rapid increase in the prevalence of DM is mainly due to lack of physical activity, unhealthy eating habits, stress, and improper processed food items which cause obesity and diabetes (diabesity). The currently available oral antidiabetic drugs and insulin are beneficial in managing chronic hyperglycemia but not efficient to manage diabetes-associated complications. Moreover, these agents are also responsible for the development of several side effects such as anemia, allergic reactions, thrombocytopenia, lactic acidosis, leucopenia, liver failure, and optic diseases. Due to the rapid increase in the number of DM cases, there is an urgent need to establish novel therapeutic agents to combat the situation (Aamir *et al.*, 2021).

The utilization of ethnobotanicals for the treatment of several diseases is very well established. These natural agents possess medicinal properties and in the last few years, phytochemicals are intensively investigated in various preclinical studies. Additionally, the use of natural agents is also beneficial in terms of safety and efficacy to treat people of different age groups. The isolated plant extracts consist of an array of constituents *viz.* alkaloids, glycosides, saponins and phenolic compounds like flavonoids, tannins and terpenoids which possesses numerous pharmacological activities (Lahare *et al.*, 2021). Recent evidence suggested that extracts of *Curcuma longa* and (Kalaycioğlu *et al.*, 2017) *Euryale ferox salisb* (Zhang *et al.*, 2019) contain promising bioactive principles to treat DM.

Carissa grandiflora (E. Mey) A DC. synonym: *C. macrocarpa* family; Apocynaceae is a small evergreen, twiggy shrub, traditional and native to South Africa (Khan, 2019). Traditionally, leaves of the plant has been used to treat cough, rheumatism, anaemia, ulcer, fever, cold and cardiovascular diseases (Moodley *et al.*, 2011, Dhatwalia *et al.*, 2021). The whole plant was used traditionally in India and Africa to treat sexual and intestinal infections (Feyissa and Melaku, 2016, Maobe *et al.*, 2021). Also the plant is a rich source of naturally occurring ingredients and was previously claimed to have excellent anti-inflammatory property (Dhatwalia *et al.*,

*Corresponding author: e-mail: imranwaheed81@hotmail.com

2021) (Souilem *et al.*, 2019). Despite the variety of biological activities, still there is a dearth in understanding the role of *C. grandiflora* against DM. Therefore, the present work was aimed to investigate the antidiabetic potential of *C. grandiflora* extract in STZ-induced diabetic mice.

MATERIALS AND METHODS

Chemicals

Streptozotocin (BioShop® Canada Inc., STR201.1), Glibenclamide (Sanofi-Aventis, Karachi, Pakistan, G0325000), Ethanol (Merck, Darmstadt, Germany, 1070172511), Chloroform (Merck, Darmstadt, Germany, 1024452500) and n-hexane (Merck, Darmstadt, Germany, 1043912500) were purchased. All chemicals used in the current study were of analytical grade.

Plant collection and identification

Fresh Leaves of *Carissa grandiflora* were collected from paragon city, barki road Lahore Pakistan. The collected plant material was identified and authenticated by a taxonomist from the Department of Botany at Government College (G.C) University Lahore, Pakistan. A voucher specimen 3610 is on deposit at herbarium of Govt. College (GC) University, Lahore. The Leaves were dried under shade and later pulverized using herb pulverizer machine and coarse powder was stored in airtight containers. The dried powdered leaves were used for the preparation of extract.

Plant extraction

C. grandiflora leaves extracts (n-hexane, chloroform and ethanol extracts) (CGLE) was prepared by successive extraction method (Adham, 2015). Dried powdered leaves of *C. grandiflora* (850g) were macerated using n-hexane (2.5 L) for 7 days at room temperature. On 8th day, the extract was separated from the marc using muslin cloth and further filtered with Whatman filter paper. Later, filtrate was evaporated at 40°C under low pressure to get n-hexane extract. The marc obtained was dried and the process of successive extraction was repeated by remacerating the marc with 2.5L of chloroform and ethanol for 7 days (fig. 1). After one week interval, the ethanolic extract was collected by above method using rotary evaporator as shown in fig. 1. The dried extracts were stored at 4°C for future analysis. Percentage yield of all extracts was calculated by using following formula.

$$\% \text{Yield} = \frac{W_2 - W_1}{W_0} \times 100$$

(W_0 = Initial dried sample weight, W_1 = Blank container weight, W_2 = Extract with container weight)

Preliminary phytochemical screening

Primary metabolites

Phytochemical studies were carried out to determine primary metabolites such as carbohydrates, proteins, amino acids, lipids and fats following standard protocols (Sawant and Godghate, 2013, Trease and Evans, 1989,

Nawaz *et al.*, 2020). Lead acetate solution was used to remove chlorophyll from the extracts. The Molish, Fehling (Al Jamal and Al Yousef, 2018), Benedict (Benedict, 1909, Al Jamal and Al Yousef, 2018), Seliwanoff (Elzagheid, 2018, Besir *et al.*, 2021), and iodine tests (Fleischer, 2019) were performed for the detection of carbohydrates. While, presence of proteins and amino acids were confirmed by Millon's (Pawar and Jadhav, 2016), Biuret (Asthana *et al.*, 2019) and Ninhydrin tests (Pawar and Jadhav, 2016).

Secondary metabolites

Secondary metabolites including alkaloids, glycosides, terpenoids, tannins, phenolic compounds and flavonoids were tested as per standard protocols (Sawant and Godghate, 2013, Trease and Evans, 1989, Nawaz *et al.*, 2020). The alkaloids were confirmed by using Dragendorff's (Raal *et al.*, 2020), Mayer (Pawar and Jadhav, 2016), Wagner's and Hager's test (Pawar and Jadhav, 2016). The glycosides were confirmed by Legal test (Pawar and Jadhav, 2016), Keller-Killani test (Sawant *et al.*, 2013, Shaikh and Patil, 2020), and Baljet test (Shaikh and Patil, 2020). The terpenoids were detected by salkowski test (Malik *et al.*, 2017, Kiruthiga and Sekar, 2014). The presence of tannins was confirmed by the ferric chloride (Asthana *et al.*, 2019) and gelatin test (Sawant *et al.*, 2013). While, the presence of phenolic compounds and flavonoids were confirmed by lead acetate (Sawant *et al.*, 2013, Shaikh and Patil, 2020), bromine water (Shaikh and Patil, 2020), and Flavonoid test I and II respectively (Sawant *et al.*, 2013, Shaikh and Patil, 2020).

Fourier transform infrared spectroscopy (FTIR)

FTIR (Nicolet 6700, Thermo Fisher Scientific, USA) was used for functional group analysis of CGLE. The apparatus was equipped with a temperature stabilized detector for the analysis in the range of 400-4000 cm^{-1} (Sawant *et al.*, 2013, Shaikh and Patil, 2020).

Thin layer chromatography (TLC) profiling

Thin Layer Chromatography (TLC) of *C. grandiflora* extracts was performed on pre-coated silica glass plates of analytical grade. In the present study, two different gradient solvent systems viz. hydrophilic phase (Chloroform: Ethanol: Water - 80:20:2) and lipophilic phase (Ethyl acetate: Methanol: Water - 100:16.5:13.5) were used as mobile phase. Concentrated CGLE samples were diluted with the respective solvents (n-hexane, chloroform, and ethanol) and spotted in preparative TLC plates and were run individually in both solvent systems. Then TLC plates were visualized with a UV short wavelength of 254 nm and with a long wavelength of 365 nm (Giri *et al.*, 2020).

DPPH radical scavenging assay

The 2,2-diphenyl-1-picrylhydrazyl (DPPH) free radical scavenging assay was used to determine the antioxidant

activity of CGLE (*n*-hexane, chloroform and ethanol) samples (Giri *et al.*, 2020). Briefly, different concentrations (100, 200, 500 and 1000 ppm) of CGLE and 100 ppm of Ascorbic acid (Standard) were prepared and to this 2 ml of DPPH (0.16mM in methanol) was added and vortexed for 1 min. The mixture was allowed to stand at 25°C for 30 min in dark and absorbance was read at 517 nm. The DPPH scavenging (%) property of CGLE and control was calculated by using the following formula:

$$\% \text{ Inhibition} = \frac{A_{\text{DPPH}} - A_{\text{Sample}}}{A_{\text{DPPH}}} \times 100$$

A_{DPPH} is the absorbance of control and A_{sample} is the absorbance of the extract. The IC_{50} values were calculated using linear regression analysis and used to indicate antioxidant capacity. The half-maximal inhibitory concentration (IC_{50}) value was calculated from the graph plotted between the percentage of scavenging and concentration (fig. 3). Lower absorbance of the reaction mixture indicates higher free radical activity. These measurements were performed in triplicate.

In vivo studies

Experimental animal

Six to eight-week-old male CD-1 mice ($n = 45$) weighing $25 \pm 7g$ were purchased from the animal house of The University of Lahore. All mice were acclimatized for a week and kept under standard laboratory conditions (Temp $24 \pm 1^\circ C$, humidity $55 \pm 5\%$, with 12h LD cycle). The experimental protocols were approved by Institutional Research Ethics Committee with Ethics No. IREC-2019-128. All animals were weighed and their body weights were recorded individually before the administration of CGLE. The volume of the CGLE was computed based on the body weight of the individual mice. All mice were non-gravid and nulliparous and provided with a standard pallet diet and water *ad libitum*.

Induction of diabetes

DM was induced via a single intraperitoneal (IP) injection of streptozotocin (STZ) (40 mg/kg) dissolved in freshly prepared 0.1M cold sodium citrate buffer (pH 4.5) in overnight fasted animals (Furman, 2015, Joshua *et al.*, 2020, El-Ghazawy *et al.*, 2020, Liu *et al.*, 2013). While normal control received only sodium citrate buffer. Development of DM was confirmed by measuring Fasting blood glucose (FBG) after 72 hours of STZ administration. The blood sample was taken by pricking tail-vein and FBG was measured immediately by glucometer (ACCU-CHEK Performa (Roche, Germany)). The same procedure was repeated on all mice after 7 days of STZ treatment. Animals were considered diabetic with FBG of more than 250mg/dl.

Experimental design

After successful induction of the diabetic state, mice were divided into 9 groups containing 5 mice in each ($n=5$). Group 1 and 2: Normal control and diabetic control respectively, received orally 0.9% normal saline, Group 3:

Positive control treated orally with Glibenclamide (GLIB) 10mg/kg, Group 4 and 5: Diabetic mice orally administered with *C. grandiflora* *n*-hexane extract 100mg/kg, and 200mg/kg respectively, Group 6 and 7: Diabetic mice orally administered with *C. grandiflora* Chloroform extract 100mg/kg and 200mg/kg respectively, Group 8 and 9: Diabetic mice orally administered with *C. grandiflora* ethanol extract 100mg/kg, and 200mg/kg respectively. Food and water intake were measured on daily basis, while body weight was recorded weekly and blood glucose was measured twice a week. Two doses of 100 and 200mg/kg of *n*-hexane, chloroform, and ethanol extracts were given orally for 15 days via oral gavage.

Histopathology

On the 15th day, all animals were euthanized to harvest kidneys, pancreas and liver. The harvested tissues were cut into small pieces and placed in 10% formalin solution (Kanter *et al.*, 2009, Sudjarwo *et al.*, 2017) and later send to a diagnostic lab in the hospital of The University of Lahore. Briefly, tissue samples were placed in Bouin's solution for 12 hrs. The samples were treated with 70%, 80%, 90%, and absolute alcohol in series, then fixed in paraffin wax, and later cut into small sections (5mm) using a microtome. The hematoxylin-eosin (H&E) stain was used to highlight histomorphological alterations in the tissue architecture. The morphological changes in the pancreas, liver, and kidney were observed under a light microscope (Eclipse Ci-L; Nikon Instruments, Inc) in the department of pathology, University College of Medicine & Dentistry (UCMD), University of Lahore.

STATISTICAL ANALYSIS

The results were expressed as mean \pm standard error mean. The Statistical significance was assessed using one-way analysis of variance (ANOVA) followed by *post-hoc* analysis using SPSS V 20.0 IBM INC. USA. Differences were considered significant at $P < 0.05$.

RESULTS

Extract yield

The percentage yield of the *n*-hexane extract was 1.477%, chloroform extract was 3.096% and the ethanol extract was 9.29%. The percentage yield of ethanol extract was high as compared to the other two extracts.

Preliminary phytochemical analysis

The preliminary phytochemical analysis of the primary and secondary metabolites confirmed the presence of carbohydrates (reducing sugars) in all three solvent extracts of *C. grandiflora*. Ketose sugars such as fructose or sucrose are present only in ethanol extract. Proteins are absent in all three extracts. However, traces of amino acids; proline or hydroxyl proline were detected in the chloroform and ethanol extracts. On the other hand,

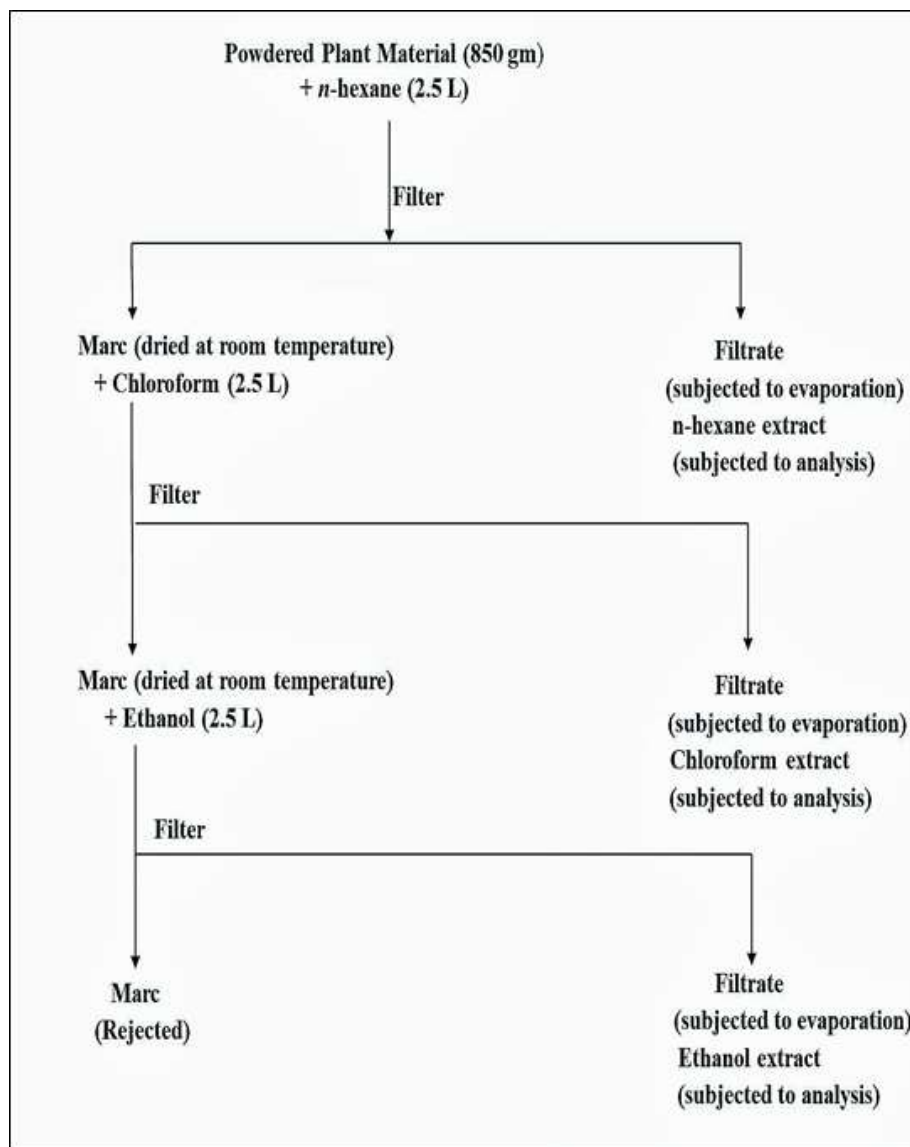


Fig. 1: Schematic diagram representing *C. grandiflora* leaves extraction process.

alkaloids, flavonoids, terpenoids, tannins and glycosides (cardenolides) were detected in all three extracts as shown in table 1.

Fourier transform infrared spectroscopy (FTIR)

The FTIR indicated the presence of important functional groups like phenol, aldehyde, ketone, alkene, alkyne, alcohol, benzene ring, and amines by different peaks. FTIR of n-hexane, chloroform and ethanol extracts was performed and the results are shown in fig. 2.

The more intense bands occurring at 2921.09 cm^{-1} , 2850.91 cm^{-1} , 1733.92 cm^{-1} , 1452 cm^{-1} , 1376.32 cm^{-1} , 1172.36 cm^{-1} , 1077.30 cm^{-1} , 1024.50 cm^{-1} , 968.92 cm^{-1} , 879.69 cm^{-1} , 828.29 cm^{-1} , 720.60 cm^{-1} , 653.75 cm^{-1} corresponds to O-H, C-H, C=O, C-H, C-O, C-N, C=O, C-Br, C-Cl and C=C stretching/bending vibrations respectively indicated the presence of amino acids, alkenes, ether, nitrates, ester, organic halogen

compounds and carbohydrates in n-hexane leaves extract of *C. grandiflora*. Brominate compounds show an infra-red region 500-750 cm^{-1} . The very strong absorption was observed around 2957.37 cm^{-1} , 2848.88 cm^{-1} , 1733.61 cm^{-1} , 1687.85 cm^{-1} , 1407.47 cm^{-1} , 1377.42 cm^{-1} , 1243.16 cm^{-1} , 1166.92 cm^{-1} , 1056.37 cm^{-1} , 878.9 cm^{-1} , 720.28 cm^{-1} , 598.77 cm^{-1} , 513.31 cm^{-1} corresponds to N-H, O-H, C=O, C=N, O-H, C-N, C-O, C-H, C-Cl and C-I stretching/bending vibrations respectively indicated the presence of amine salts, alcohol, aldehyde, imine/oxime, phenol, primary alcohol and benzene in chloroform extract of *C. grandiflora*. The more intense bands occurring at 3325.77 cm^{-1} , 2975.89 cm^{-1} , 1609.62 cm^{-1} , 1521.12 cm^{-1} , 1381.93 cm^{-1} , 1284 cm^{-1} , 1083.18 cm^{-1} , 1043.16 cm^{-1} , 877.71 cm^{-1} corresponds to N-H, O-H, C-H, C=C, N-O, C-H, C-O, S=O, C-C stretching/bending vibrations respectively indicated the presence of amine salts, alcohol, alkene, nitro compound, alkane, aromatic salts,

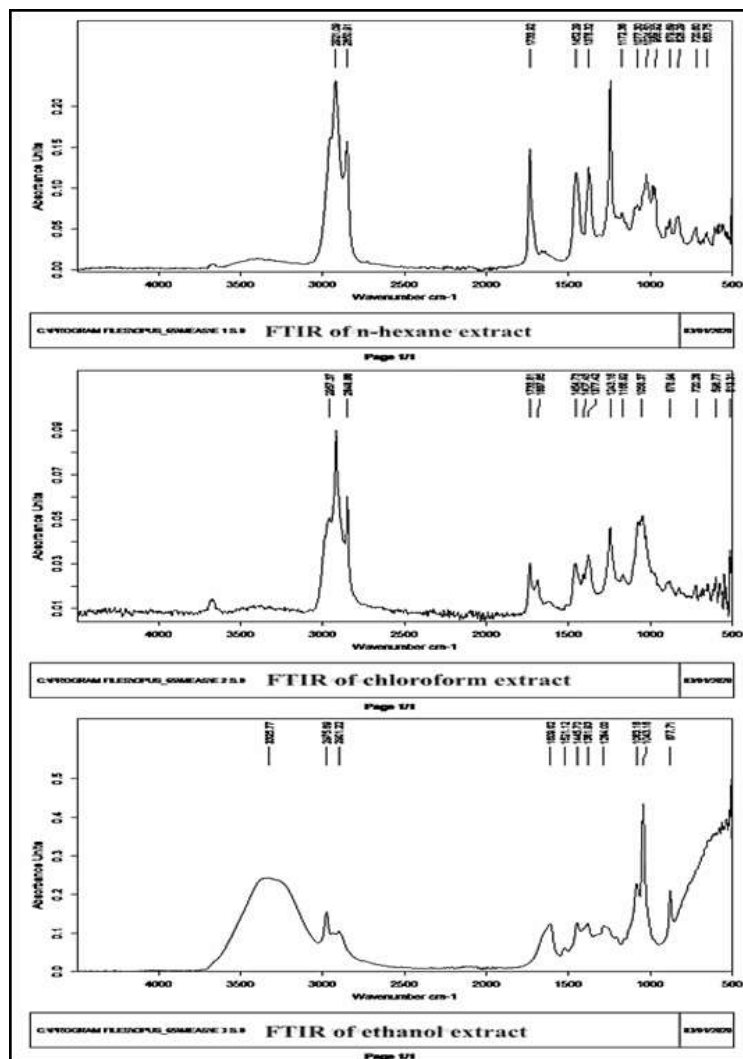


Fig. 2: FTIR scans of *C. grandiflora* extracts (n-hexane, chloroform and ethanol)

primary alcohol, sulfoxide and alkene in ethanol leaves extract of *C. grandiflora*. There is no absorbance in between the region 2200-2260 cm^{-1} indicates that no cyanide groups in all three extracts. Based on our results it is clear that all three extracts of *C. grandiflora* do not contain any toxic substances.

Thin layer chromatography

The TLC profiling of CGLE were performed in two different gradient solvent such as lipophilic (Chloroform: Ethanol: Water) and hydrophilic (Ethyl acetate: Methanol: Water) system were observed in short UV and long UV. In the lipophilic phase system n-hexane and chloroform extracts showed three spots (0.85, 0.88 and 0.55) and (0.94, 0.89, and 0.96) respectively. While ethanol extract presented two spots (0.90 and 0.87). The spots shown by n-hexane and chloroform were located at the lower level of the plate which highlighted the lipophilic nature of the extract. In the hydrophilic phase, four spots were shown by n-hexane extract (0.87, 0.89, 0.88, 0.92), two spots presented by chloroform extract (0.83, 0.87) and ethanol

extract showed three spots (0.77, 0.12 and 0.08). Interestingly, n-hexane and ethanol extracts gave a maximum number of spots in the hydrophilic phase.

Antioxidant activity

Among the three (n-hexane, chloroform and ethanol) extracts of *C. grandiflora* tested for antioxidant potential. Chloroform extract showed remarkably pronounced activity with respect to the standard (ascorbic acid); whereas it was considerably lesser in chloroform and ethanol extract. The IC_{50} value obtained were 531.34 for ascorbic acid, 648.50 for n-hexane, 529.66 for chloroform and 584.79 for ethanol extracts. The radical scavenging effect of CGLE was close to standard ascorbic acid as shown in the fig. 3. The presence of phenolic compounds and flavonoids in plant prevent the threat of oxidative stress and act as free radical scavengers. Thus, results of antioxidant assay substantiated that radical scavenging property was markedly pronounced in higher concentration of extract.

Table 1: Primary and Secondary metabolites of *C. grandiflora* extracts

Constituents	Observation		
	n-hexane Extract	Chloroform Extract	Ethanol Extract
Carbohydrates	++	+++	+++
Amino acid	+	+	++
Alkaloids	++	++	+++
Glycosides	+	++	+++
Terpenoids	+++	++	+++
Tannins	+	++	++
Phenolic compounds	+	++	++
Flavonoids	++	++	+++

(-) Negative results, (+) Slightly present, (++) Moderately present, (+++) highly present

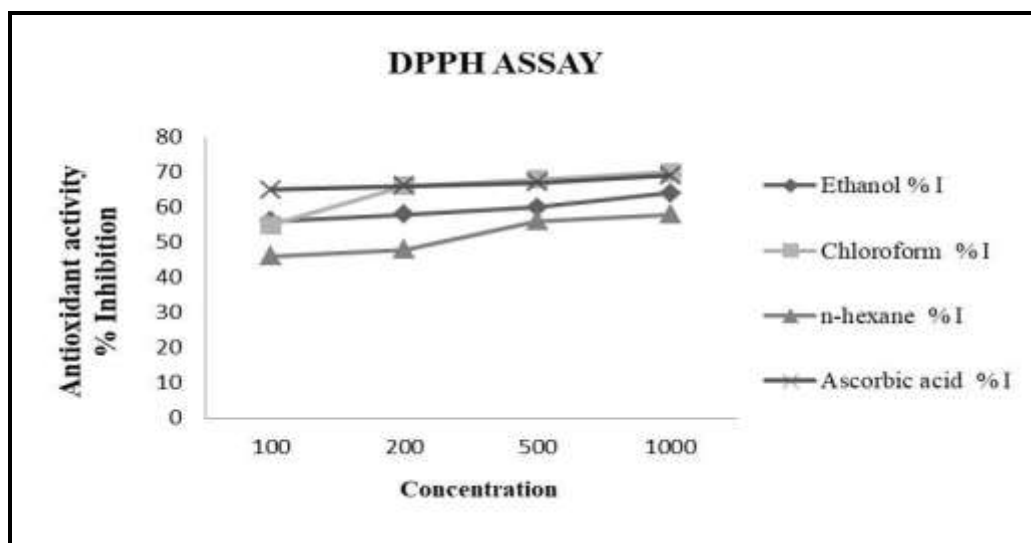


Fig. 3: DPPH free radical scavenging activity of different concentrations of CGLE and ascorbic acid

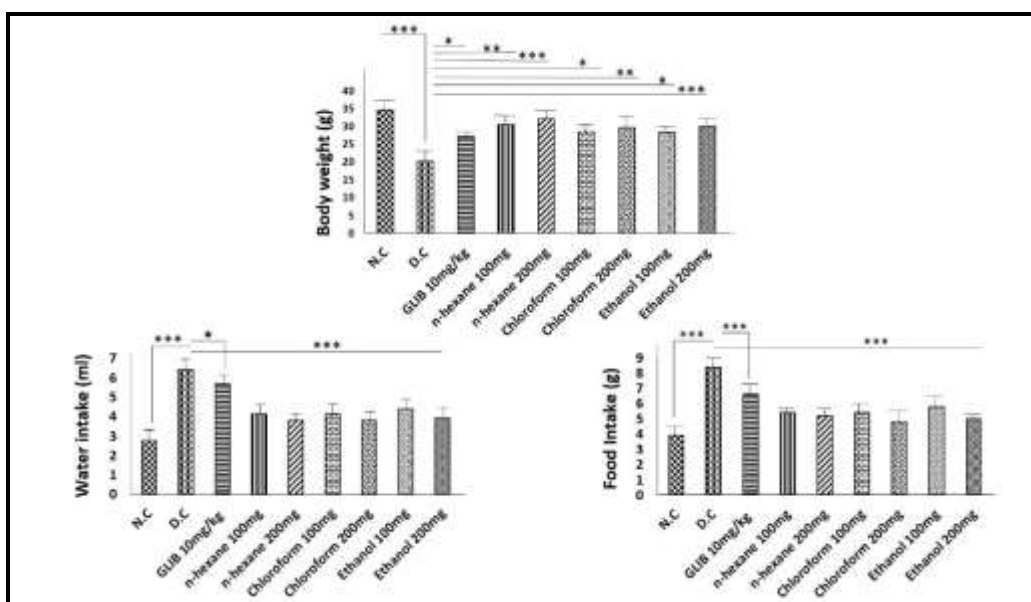


Fig. 4: Effect of CGLE on BW, FI and WI. Bars representing mean \pm SD followed by One-way ANOVA and Tukey's range test. NC normal control; DC diabetic control; GLIB glibenclamide. Non-significant (ns), * $p < 0.05$, ** $p < 0.005$, *** $p < 0.001$, when compared with DC.

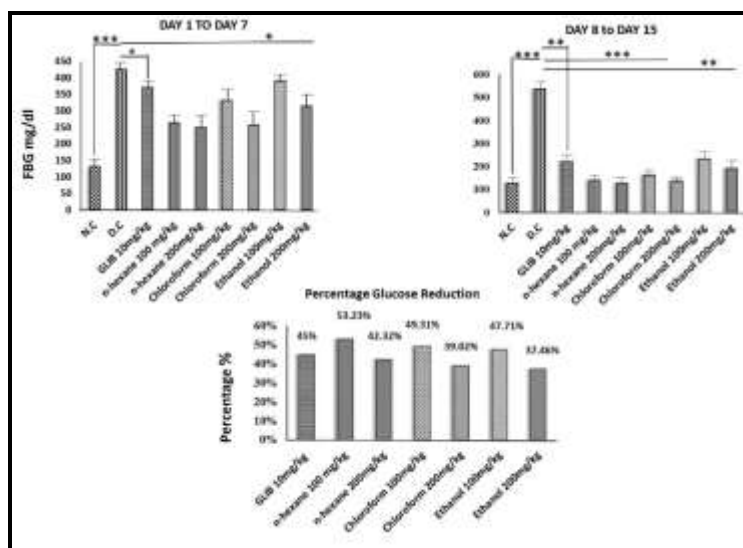


Fig. 5: Effect of CGLE on fasting blood glucose (FBG). Bars representing mean \pm SD followed by One-way ANOVA and Tukey's range test. NC normal control; DC diabetic control; GLIB glibenclamide. Non-significant (ns), * $p < 0.05$, ** $p < 0.005$, *** $p < 0.001$, when compared with DC.

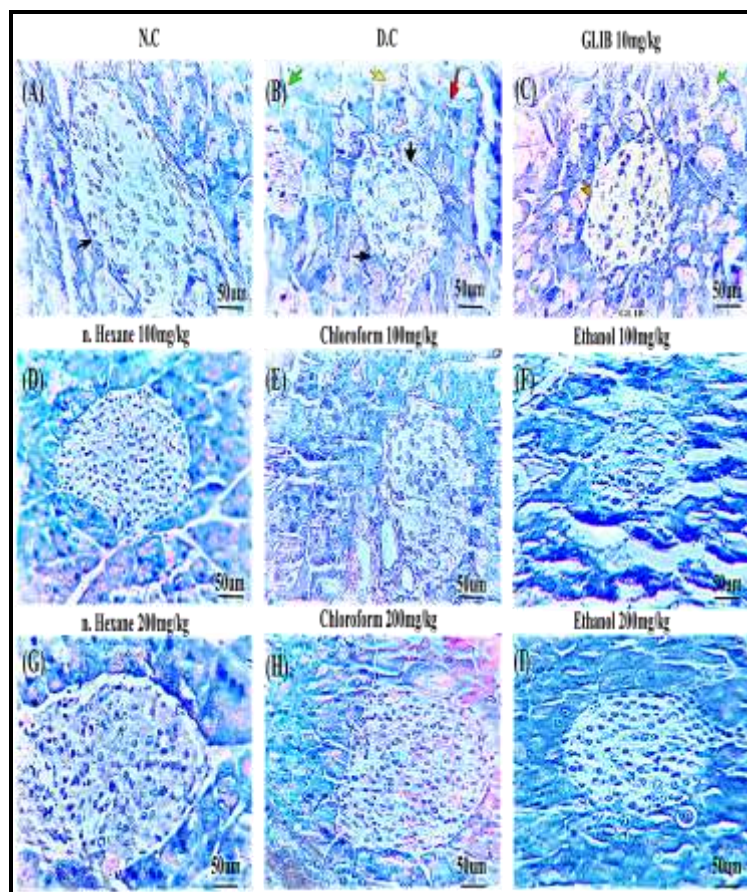


Fig. 6: Photomicrographs of H/E-stained pancreas of mice from different groups. (A) Normal control showed regular morphology of pancreas with intact islets of Langerhans and granulated cytoplasm. (B) Diabetic control displayed disrupted histoarchitecture with reduced islets size and number and vacuolated cytoplasm. (C) Glibenclamide treatment showed slight improvement in the morphology of diabetic pancreas. (D&E) *C. grandiflora* n-hexane extract 100 and 200 mg/kg showed marked improvement in the overall structure of pancreas. (F&G) *C. grandiflora* chloroform extract 100 and 200 mg/kg presented minor improvements with slightly dark stained islets and vacuolated cytoplasm. (H&I) *C. grandiflora* ethanol extract 100 and 200 mg/kg represented remarkable improvement in acinar morphology, shape and number of islets. The black arrow; islets of Langerhans, The green arrow; fluid accumulation. The red arrow; acinar cell vacuolization, The orange arrow; damaged islets of Langerhans (H&E stain x400).

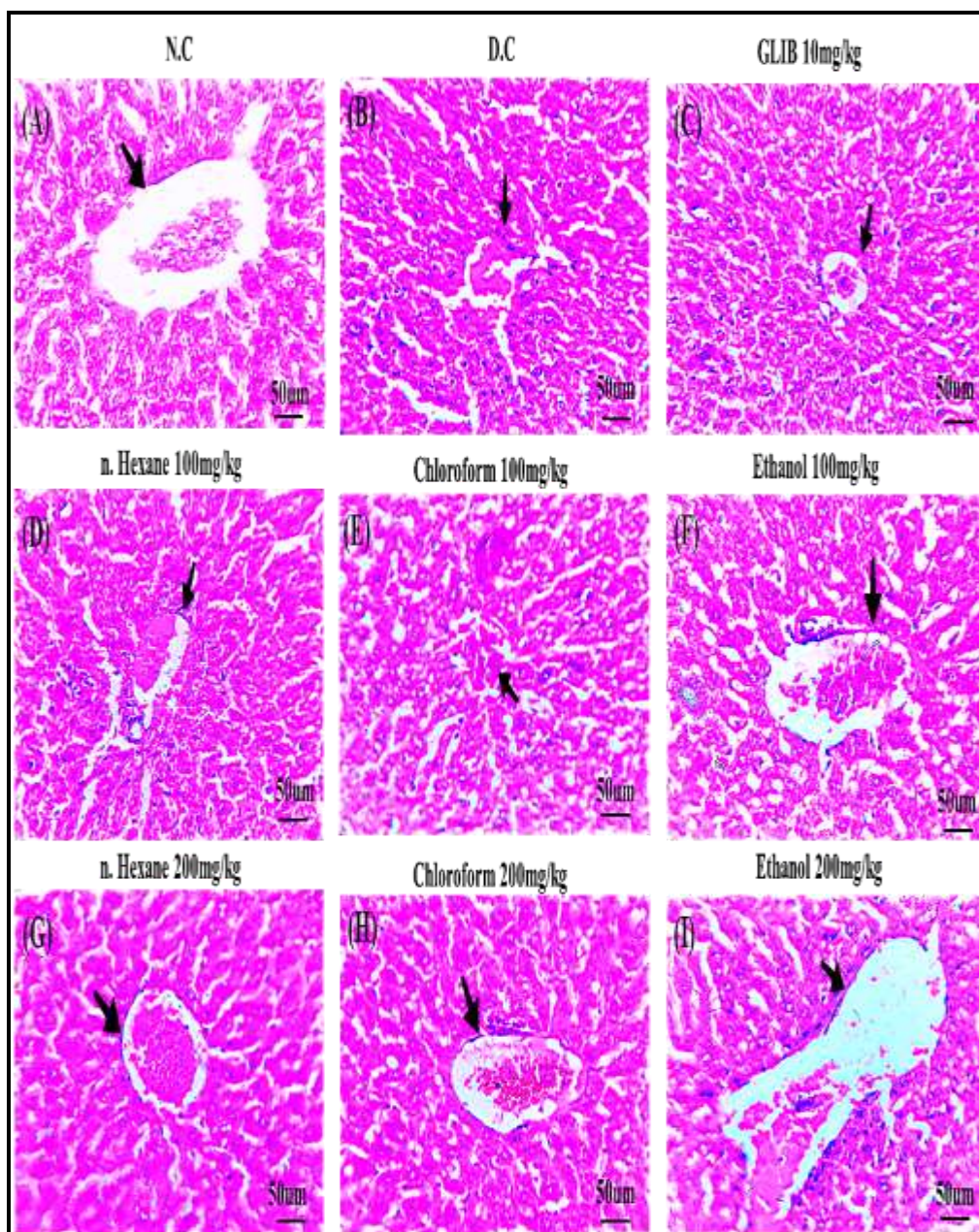


Fig. 7: Photomicrographs of H/E-stained liver of mice from different groups. (A) Normal control showed intact lobular architecture and regular morphology of hepatocytes (B) Diabetic control reflecting destructed hepatic architecture with marked cytoplasmic and nuclear vacuolization. (C)Glibenclamide treatment showed restoration of lobular architecture but with nuclear vacuolization.(D&E)*C. grandiflora* n-hexane extract100 and 200 mg/kg ameliorated nuclear vacuolization and signs of necrosis.(F&G) *C. grandiflora* chloroform extract 100 and 200 mg/kg displayed improvement in the polygonal structure and cytoplasmic condensation.(H&I) *C. grandiflora* ethanol extract100 and 200mg/kg showed restoration of the intact lobular architecture and repair damaged liver to some extent.(H&E stain x400).

Effect of CGLE on body weight, polyphagia and polydipsia

Non-treated diabetic mice showed a massive reduction in body weight (BW) with significant polyphagia and polydipsia when compared with normal control ($P<0.05$). Conversely, two weeks of CGLE extract treatment of diabetic mice significantly improved BW of mice ($P<0.05$). Moreover, CGLE treatment (n-Hexane, Chloroform, Ethanol) considerably ameliorated

polyphagia and polydipsia ($P<0.05$) as shown in fig. 4. The 200 mg/kg CGLE effectively prevented weight reduction, polyphagia and polydipsia in STZ-induced diabetic mice.

Effect of CGLE on FBG

FBG level of untreated diabetic mice (diabetic control group) was significantly increased during the study as compared to normal control ($p<0.05$). During 1st week all

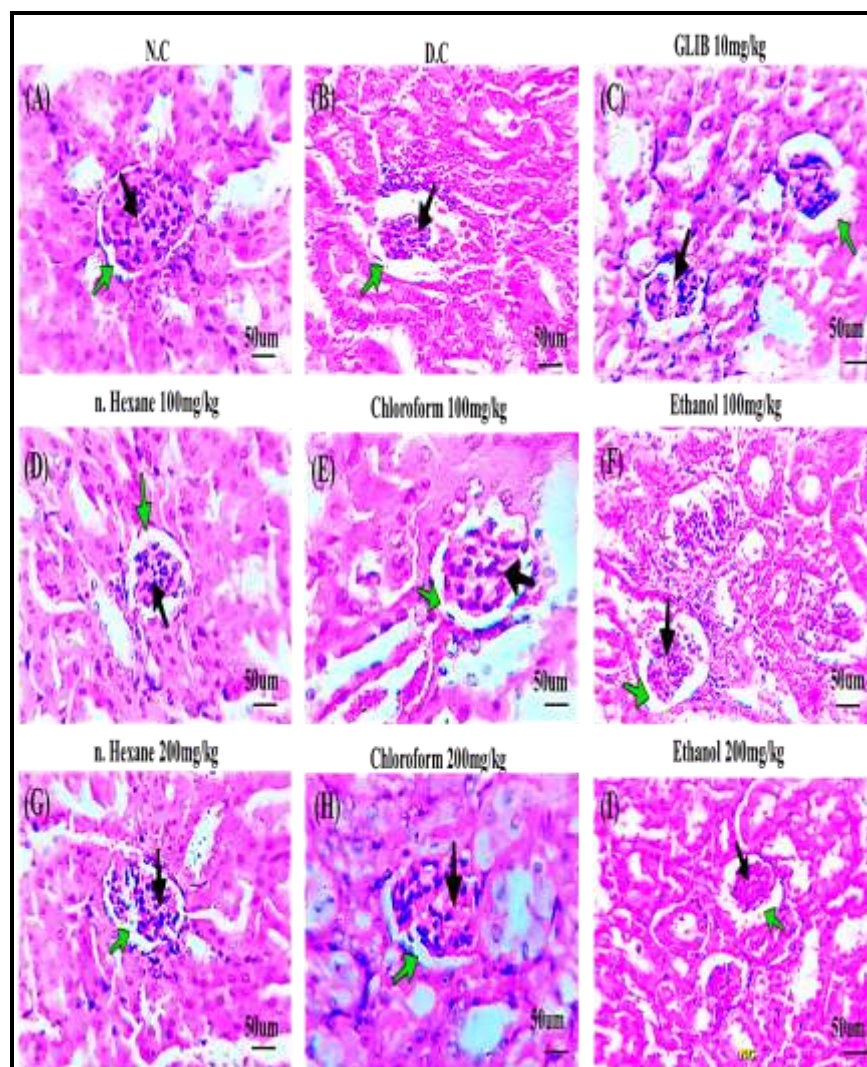


Fig. 8: Photomicrographs of H/E-stained kidney of mice from different groups. (A) Normal control showed no variation in the histo architecture of glomerular structure and normal appearance of nephron. (B) Diabetic control displayed abnormal morphology of glomerular structure with enlarge urinary space and necrotic signature. (C) Glibenclamide treatment revealed mild recovery of renal histomorphology but still wide urinary spaces are visible (D&E) *C. grandiflora* n-hexane extract 100 and 200 mg/kg reflected moderate improvement in renal architecture and slight reduction in necrosis (F&G) *C. grandiflora* chloroform extract 100 and 200 mg/kg showed almost similar renal histomicrograph as n-hexane extract. (H&E) *C. grandiflora* ethanol extract 100 and 200 mg/kg highlighted very slight improvement in the tissue morphology as compared to other treatment groups. The black arrow; bowman s capsule, The green arrow; urinary space (H&E stain x400).

diabetic animals treated with n-hexane, chloroform and ethanol CGLE extract (100 and 200mg/kg) showed a significant reduction in FBG when compared with the negative and positive control ($p < 0.05$). While during 2nd week of CGLE treatment, all extracts (100 and 200 mg/kg) showed a massive reduction in FBG ($P < 0.001$) as compared to non-treated diabetic mice. Overall analysis revealed percentage reduction in the FBG by glibenclamide was 45%; whereas maximum reduction was shown by 100mg/kg n-hexane extract which was 53.23% after 15 days. This outcome highlighted that n-hexane extract (100 mg/kg) showed more promising results in reducing blood glucose. On the other hand, CGLE chloroform extract (100 and 200mg/kg) reduced

FBG by 49.31% and 39.02% respectively. However, CGLE ethanol extract (100 & 200mg/kg) showed percentage reduction of 47.71% and 37.46% respectively when compared with control as shown in the fig. 5.

Effects CGLE on histopathology of pancreas, liver and kidney

Pancreas

Histomorphological observation of H&E-stained pancreatic section from non-diabetic mice revealed regular architecture of the tissue. The islets of Langerhans were rounded in shape, enclosed in pale stained region. The exocrine portion showed normal histological organization with regular arrangement of acinar and

pyramidal cells as shown in fig. 6A. On the other hand, STZ triggered various alteration in the pancreatic histology of non-treated diabetic mice. Reduction in islets number, necrosis and apoptosis were evident from the fig. 6B. Treatment with n-hexane, chloroform, and ethanol CGLE extracts (100 & 200mg/kg) and glibenclamide showed remarkable improvements in the histo-architecture of the pancreas. The number and size of islets were improved while; acinar cells restored their morphology in treated diabetic mice as compared to diabetic control animals (fig. 6).

Liver

Histopathological analysis of liver section from normal animals revealed intact lobular structure without any pathological feature (fig. 7A). While, non-treated diabetic mice showed condensation of nuclear chromatin with marked nuclear and cytoplasmic vacuolization due to STZ induced hyperglycemia (fig. 7B). Treatment with glibenclamide and CGLE extracts ameliorated nuclear and cytoplasmic condensation with reduced necrosis and apoptosis (fig. 7).

DISCUSSION

The current study was conducted for preliminary phytochemical analysis and to investigate antidiabetic potential of n-hexane, chloroform and ethanolic extracts of *Carissa grandiflora* leaves on STZ induced diabetic mice. *C. grandiflora* a shrub bearing shiny and lush green leaves from the family Apocynaceae exhibit extreme medicinal importance. Previously, various studies highlighted biological and chemical importance of some plants from this family (Abdallah and Khalid, 2012, Rehman *et al.*, 2013). In the present research work, the preliminary qualitative analysis for the primary and secondary metabolites (as presented in table 1), has indicated the presence of different important classes of phytochemicals in the studied extracts.

DM is a complex metabolic syndrome characterized by abnormal secretion and function of insulin resulting in hyperglycemia (Fröde and Medeiros, 2008, Goyal and Jialal, 2018). The currently available therapeutic options for the management of DM are able to keep blood glucose level within normal range but associated with various adverse effects. Due to large number of adverse effects related to synthetic drugs, preclinical research is now directed to explore natural products capable to ameliorate symptoms of DM (Tomic *et al.*, 2022). The STZ is a well-established diabetogenic agent to induce diabetes in preclinical research (Raubbun *et al.*, 2020). Mechanistically, after uptake of STZ by pancreatic β -cells, nitrosourea moiety present in streptozotocin causes DNA destruction and induces cell death (Jarald *et al.*, 2008, Goyal and Jialal, 2018). The β -cell death is associated with three major ways including methylation of DNA (Karunakaran *et al.*, 2022), formation of free

radicals and production of nitric oxide (Jarald *et al.*, 2008, Sharma *et al.*, 2008, Ochalefu *et al.*, 2018). In the present work, diabetes like condition was induced via single IP injection of STZ and development of model was confirmed after critical monitoring of BW and FBG of animals. All animals showed hyperglycemia and loss in BW after STZ treatment.

The gradual loss in BW is a cardinal feature of diabetes in humans and significant fall in BW is directly related to deterioration of structural proteins, dehydration and breakdown of fats (Tan *et al.*, 2023). Additionally, BW loss is also linked with reduced insulin release and defect in energy production due to altered glucose and fat metabolism (Gotama and Amir Husni, 2018). The outcomes of the present work revealed gradual emaciation of the untreated diabetic mice while, treatment with the CGLE extract significantly improved BW loss in treated groups. Thus, highlighting improvement in insulin release from the remaining β -cells. Conversely, excessive food and water intake also linked with reduced insulin level during DM. In addition, altered insulin release leads to leptin dysfunction at cellular level (Aamir *et al.*, 2021). Nonetheless, treatment with CGLE significantly reversed these metabolic events in diabetic mice.

Increase level of FBG is the early symptom of diabetes which is linked with disruption of glycolysis (Manna *et al.*, 2010). The oral ingestion of CGLE n-hexane, chloroform and ethanol extracts (100 and 200 mg/kg) significantly reduced FBG in treated diabetic mice after 15 days treatment as shown in fig. 5. The possible antihyperglycemic effect of *C. grandiflora* extracts could be mediated through β -cells repair and enhanced secretion of insulin. The antihyperglycemic effect of CGLE extracts was comparable with glibenclamide. Therefore, it is possible that *C. grandiflora* may act by similar mechanism as glibenclamide. On the other hand, generation of reactive oxygen species (ROS) plays a major role in the pathology and advancement of DM. Moreover, STZ also liberate nitric oxide (NO) during intracellular metabolism which is combined with ROS to generate several reactive intermediates leads to excessive production of pro-inflammatory cytokines (Aamir *et al.*, 2020). In this context, our CGLE extract demonstrated excellent antioxidant property in DPPH assay and could scavenge reactive nitrogen species (RNS) and ROS to ameliorate oxidative stress due to hyperglycemia.

The antidiabetic effect of CGLE could be mediated by flavonoids. Flavonoids have several health benefits and implicated in cancer, cardiovascular disorder, obesity and diabetes. Antioxidant property of flavonoids is well established and plays an important role in neutralizing RNS and ROS to ameliorate DM. Importantly, flavonoids are actively involved in the regeneration of β -cells, enhance insulin release and improve blood glucose by

modulating hepatic glucose metabolism (Al-Ishaq *et al.*, 2019). Therefore, presence of flavonoids in the CGLE extract could be attributed to its antioxidant property and antidiabetic effect. These outcomes are in line with the study conducted by Gebremeskel and his colleagues who showed antidiabetic potential of *Becium grandiflorum* via β -cells regeneration, α -glycosidase inhibition and enhanced activity of glucose uptake transporters (Gebremeskel *et al.*, 2020).

Next, we examined histomorphological features of pancreas, liver and kidney. H&E staining of pancreatic section from non-treated diabetic mice revealed structural modification, reduction in islets cell size and number with necrotic and apoptotic signature. Treatment with CGLE extract significantly reversed these alterations in the treated groups which is evident from the reduced FBG and improved BW. Similarly, altered histoarchitecture of liver and kidney was effectively restored after 15 days of orally administered CGLE extract. Several mechanisms have been associated with organ damage during diabetes. Activation of inflammatory pathways due to hyperglycemia and ROS leads to generation of proinflammatory cytokines which further exaggerate endoplasmic reticulum and oxidative stress. Collectively, these pathological events directed damage to internal organs (Halban *et al.*, 2014).

Further, CGLE extract had also effectively improved BW and FBG during diabetic state which could be correlated with the presence of phytochemicals detected during initial phytochemical screening. The outcomes might be attributed towards repairing of damaged pancreatic β -cells due to oxidative stress. Moreover, antioxidant property of the *C. grandiflora* might reduce ROS and RNS production in pancreas, liver and kidney to restore tissue damage under hyperglycemia.

CONCLUSION

The present study revealed the presence of primary and secondary metabolites and functional groups in the *C. grandiflora* (*n*-hexane, chloroform, and ethanol) extracts with marked antioxidant properties. In addition, our outcomes clearly highlighted the antidiabetic potential of *C. grandiflora* extract by reducing FBG and improving the BW of diabetic animals. However, future investigations are needed to isolate important compounds from the extract to elucidate the exact mechanism of the antihyperglycemic effect at the cellular and molecular levels. Long-term efficacy and dose-dependent response should be analyzed in the sub-acute model of DM.

ACKNOWLEDGMENT

The present work is supported by the Faculty of Pharmacy, The University of Lahore.

REFERENCES

- Aamir K, Khan HU, Hossain CF, Afrin MR, Jusuf PR, Waheed I, Sethi G and Arya A (2021). Arjunolic acid downregulates elevated blood sugar and pro-inflammatory cytokines in streptozotocin (STZ)-nicotinamide induced type 2 diabetic rats. *Life Sci.*, **289**(5): 120232.
- Aamir K, Khan HU, Sethi G, Hossain MA and Arya A (2020). Wnt signaling mediates TLR pathway and promote unrestrained adipogenesis and metaflammation: Therapeutic targets for obesity and type 2 diabetes. *Pharmacol Res.*, **152**(8): 104602.
- Abdallah EM and Khalid AE (2012). A preliminary evaluation of the antibacterial effects of *Commiphora molmol* and *Boswellia papyrifera* oleo-gum resins vapor. *Int. J. Biol. Chem. Sci.*, **1**(2012): 1-15.
- Adham AN (2015). Comparative extraction methods, phytochemical constituents, fluorescence analysis and HPLC validation of rosmarinic acid content in *Mentha piperita*, *Mentha longifolia* and *Osimum basilicum*. *J. Pharmacogn. Phytochem.*, **3**(6): 130-139.
- Al-Jamal and AL Yousef (2021). Phytochemical analysis of some herbal medicines. *Natrosa Lett.*, **2**(2): 56-58.
- Al-Ishaq, Abotaleb M, Kubatka P, Kajo K and Busselberg D (2019). Flavonoids and their anti-diabetic effects: cellular mechanisms and effects to improve blood sugar levels. *Biomolecules.*, **9**(9): 430.
- Asthana S, Maurya S P, Maurya P and Maurya A (2019). Qualitative analysis of protein: Egg albumin and milk. *IJOD.*, **7**(1): 30-33.
- Benedict S. (1909). A reagent for the detection of reducing sugars. *J. Biol. Chem.*, **5**(5): 485-487.
- Besir A, Yazici F, Mortas M and Gul O (2021). A novel spectrophotometric method based on Seliwanoff test to determine 5-(Hydroxymethyl) furfural (HMF) in honey: Development, in house validation and application. *LWT.*, **139**: 110602.
- Dhatwalia J, Kumari A, Verma R, Upadhyay N, Guleria I, Lal S, Thakur S, Gudeta K, Kumar V and Chao J (2021). Phytochemistry, pharmacology and nutraceutical profile of carissa species: An updated review. *Molecules.*, **26**: 7010.
- El-Ghazawy Y M, EL-Zainy M A and Hassan R (2020). Histological and immunohistochemical analysis of green coffee aqueous extract effect on parotid salivary gland in streptozotocin induced diabetic albino rats. *Egypt. J. Histol.*, **43**(3): 748-762.
- Elzagheid M (2018). Laboratory activities to introduce carbohydrates qualitative analysis to college students. *World. J. Chem. Educ.*, **6**(2): 82-86.
- Feyissa D and Melaku Y (2016). Phytochemical, antibacterial and antioxidant studies of the leaves of *Carissa spinarum*. *Int. J. Chem. Pharm. Sci.*, **7**: 25-30.
- Fleischer W (2019). The iodine test for reducing sugars-a safe, quick and easy alternative to copper (II) and

- Silver (I) based reagents. *World. J. Chem. Educ.*, **7**(2): 45-52.
- Fröde T and Medeiros Y (2008). Animal models to test drugs with potential antidiabetic activity. *J. Ethnopharmacol.*, **115**(2): 173-183.
- Furman B (2015). Streptozotocin- induced diabetic models in mice and rats. *Curr. Protoc. Pharmacol.*, **70**: 5.47. 1-5.47. 20.
- Gebremeskel L, Tuem KB and Teklu T (2020). Evaluation of antidiabetic effect of ethanolic leaves extract of *Becium grandiflorum* Lam. (Lamiaceae) in streptozotocin-induced diabetic mice. *Metab. Syndr. Obes.*, **13**: 1481-1489.
- Giri S, Giri U, Subedi K, Magar K T, Pant S and Joshi K (2020). Thin Layer Chromatography (TLC) Based Chemical Profiling and Antioxidant Activity of Selected Nepalese Medicinal Plants. *J. Health. Allied. Sci.*, **10**(2): 15-22.
- Gotama T L and Amir Husni U (2018). Antidiabetic activity of *Sargassum hystrix* extracts in streptozotocin-induced diabetic rats. *Prev. Nutr. Food. Sci.*, **23**(3): 189-195.
- Goyal R and Jialal I (2018). Diabetes mellitus type 2. In: StatPearls. Treasure Island (FL): StatPearls Publishing; 2023.
- Halban P A, Polonsky K S, Bowden D W, Hawkins M A, Ling C, Mather K J, Powers A C, Rhodes C J, Sussel L and Weir G (2014). β -cell failure in type 2 diabetes: postulated mechanisms and prospects for prevention and treatment. *J. Clin. Endocrinol. Metab.*, **99**: 1983-1992.
- Joshua M T, Wachuku E O, Boisa N and Nduka N (2020). Evaluation of Antidiabetic Potentials of *Morus mesozygia* Linn. Stapf., leaf extracts in streptozotocin-induced diabetic rats. *J. Complement. Altern. Med. Res.*, **11**(1): 23-32.
- Kalaycioğlu Z, Gazioğlu I and Erim F (2017). Comparison of antioxidant, anticholinesterase and antidiabetic activities of three curcuminoids isolated from *Curcuma longa* L. *Nat. Prod. Res.*, **31**(24): 2914-2917.
- Kanter M, AKpolat M and Aktas C (2009). Protective effects of the volatile oil of *Nigella sativa* seeds on β -cell damage in streptozotocin-induced diabetic rats: a light and electron microscopic study. *J. Mol. Histol.*, **40**: 379-385.
- Karunakaran U, Elumalai S, Moon J S and Won K (2022). c-Abl tyrosine kinase inhibition attenuate oxidative stress-induced pancreatic β -Cell dysfunction via glutathione antioxidant system. *Transl Res.*, **249**: 74-87.
- Khan D (2019). Some morphological observations on leaves of *Carissa macrocarpa* (eckl.) A. DC. (family Apocynaceae). *Int. J. Biol. Biotechnol.*, **16**(4): 1027-1045.
- Kiruthiga N and Sekar D (2014). Studies on phytochemicals and Steroid Isolation from n-hexane extract of *Anisochilus carnosus*. *Int. J. Adv. Biotechnol. Res.*, **5**(3): 337-345.
- Lahare RP, Bisen YK, Yadav HS and Dashahre AK (2021). Estimation of total phenol, flavonoid, tannin and alkaloid content in different extracts of *Catharanthus roseus* from Durg District, Chhattisgarh, India. *Scholars Bulletin*, **7**(1): 1-6.
- Liu Y, Sun J, Rao S, Su Y, Li J, Li C, Xu S and Yang Y (2013). Antidiabetic activity of mycelia selenium-polysaccharide from *Catathelasma ventricosum* in STZ-induced diabetic mice. *Food. Chem. Toxicol.*, **62**: 285-291.
- Malik S, Ahmad M and Khan F (2017). Qualitative and quantitative estimation of terpenoid contents in some important plants of punjab, pakistan. *Pak. J. Sci.*, **69**(2): 150-154.
- Manna P, Das J, Ghosh J and Sil P C (2010). Contribution of type 1 diabetes to rat liver dysfunction and cellular damage via activation of NOS, PARP, I κ B α /NF- κ B, MAPKs and mitochondria-dependent pathways: Prophylactic role of arjunolic acid. *Free Radic. Biol Med.*, **48**: 1465-1484.
- Maobe M A, Gitu L and Gatebe E (2021). Evaluation of antibacterial and antifungal activity of herbs used in treatment of diabetes, malaria and pneumonia in Kisii and Nyamira Counties Region, Kenya. *J. Trop. Pharm. Chem*, **5**: 330-337.
- Moodley R, Chenia H, Jonnalagadda S B and Koorbanally N (2011). Antibacterial and anti-adhesion activity of the pentacyclic triterpenoids isolated from the leaves and edible fruits of *Carissa macrocarpa*. *J. Med. Plant Res*, **5**: 4851-4858.
- Nawaz H, Shad M A, Rehman N, Andaleeb H and Ullah N (2020). Effect of solvent polarity on extraction yield and antioxidant properties of phytochemicals from bean (*Phaseolus vulgaris*) seeds. *Brazilian J. Pharm. Sci.*, **56**: e17129.
- Ochalefu D, Adoga G, Luka C, Abu H, Amali E, Agada S and Alonyenu E (2018). Phytochemical composition and effect of *Nauclea latifolia* aqueous extracts on blood glucose levels of streptozotocin-induced diabetic wistar albino rats. *J. Biomed. Res. Clin Res.*, **1**(2): 157-163.
- Pawar S and Jadhav M (2016). Determination of extractive value and phytochemical analysis of *Bacopa monnieri* (L). *Recent Adv. Life. Sci.*, **8**: 1222-1229.
- Raal A, Meos A, Hinrikus T, Heinämäki J, Romäne E, Gudienė V, Koshovy O, Kovaleva A, Fursenco C and Chiru T (2020). Dragendorff's reagent: Historical perspectives and current status of a versatile reagent introduced over 150 years ago at the University of Dorpat, Tartu, Estonia. *Int. J. Pharm Sci.*, **75**(7): 299-306.
- Raubbin R, Laju R, Ambika P and Pushparaj A (2020). HPLC, FTIR and GC-MS analysis of ethyl acetate extract of red seaweed *Hypnea flagelliformis* Graville

- ex J. Agardh 1851. *Int. J. Pharm Sci. Res.*, **11**(8): 3953-3959.
- Rehman K, Ashraf S, Rashid U, Ibrahim M, Hina S, Iftikhar T and Ramzan S (2013). Comparison of proximate and heavy metal contents of vegetables grown with fresh and wastewater. *Pak. J. Bot.*, **45**: 391-400.
- Sawant R and Godghate A (2013). Qualitative phytochemical screening of rhizomes of *Curcuma longa* Linn. *Int. J. Sci. Environ. Technol.*, **2**: 634-641.
- Shaikh J R and Patil M (2020). Qualitative tests for preliminary phytochemical screening: An overview. *Int. J. Chem. Stud.*, **8**(2): 603-608.
- Sharma A, Shanker C, Tyagi L K, Singh M and Rao C (2008). Herbal medicine for market potential in India: An overview. *Am. J. Plant Sci.*, **1**: 26-36.
- Souilem F, Dias M I, Barros L, Calhelha R C, Alves M J, Harzallah-Skhiri F and Ferreira I (2019). Phenolic profile and bioactive properties of *Carissa macrocarpa* (Eckl.) A. DC.: An *in vitro* comparative study between leaves, stems and flowers. *Molecules*, **24**(9): 1696.
- Sudhakar M (2021). A comparative evaluation of blood sugar and glycosylated hemoglobin in clinically manifested diabetic neuropathy. *Int. J. Adv. Med.*, **8**: 212-219.
- Sudjarwo S A, Eraiko K and Giftania J (2017). Antioxidant activity of curcumine as protector on methylmercury induced-pancreas damage in mice. *J. Chin. Pharm. Sci.*, **26**(3): 196-201.
- Tan S C, Rajendran R, Bhattamisra S K, Krishnappa P, Davamani F, Chitra E, Ambu S, Furman B and Candasamy M (2023). Effect of madecassoside in reducing oxidative stress and blood glucose in streptozotocin–nicotinamide-induced diabetes in rats. *J. Pharm. Pharmacol.*, **75**(8): 1034-1045.
- Tareen R S and Tareen K (2017). Psychosocial aspects of diabetes management: dilemma of diabetes distress. *Transl. Pediatr.*, **6**: 383-396.
- Tomic D, Shaw JE and Magliano DJ (2022). The burden and risks of emerging complications of diabetes mellitus. *Nat. Rev. Endocrinol.*, **18**: 525-539.
- Trease G and Evans W (1989). Pharmacognosy (13th edn). Bailliere Tindall, London, Pp.176-180.
- Zhang W, Su R, Gong L, Yang W, Chen J, Yang R, Wang Y, Pan W, Lu Y and Chen Y (2019). Structural characterization and in vitro hypoglycemic activity of a glucan from *Euryale ferox* Salisb. seeds. *Carbohydr. Polym.*, **209**: 363-371.