

Efficacy of supratarsal triamcinolone injection in the treatment of recalcitrant vernal keratoconjunctivitis

Maham Sultan*, Fawad Rizvi, Zeeshan Kamil, Afshan Ali, Arfa Shaikh and Saima Amin

Department of Ophthalmology, Layton Rahmatulla Benevolent Trust Hospital, Karachi

Abstract: The aim is to determine the efficacy of supratarsal injections of triamcinolone acetonide among vernal keratoconjunctivitis patients not responding to the traditional topical treatment. This study was conducted at Layton Rahmatulla Benevolent Trust (LRBT) Hospital, Karachi, Pakistan. A total of 91 patients aged between 7-18 years of either gender was included. Patients were subjected to injection of triamcinolone acetonide at a dose of 0.5 ml (20 mg). The patients were followed for two weeks. Those patients who had at least fifty percent decrease in the size and number of the cobblestone papillae were followed for the next three months for any recurrence. Data was analyzed using IBM SPSS Statistics v27. The mean age of patients was 11.6 ± 3.5 years. There were 45.1% (41) females and 54.9% (50) males. The supratarsal triamcinolone injection was effective in total of 63 (69.2%) patients including 57.1% (36) males and 42.9% (27) females. None of the patients had recurrence of the papillae when followed for three months. The supratarsal injection of triamcinolone is effective in vernal keratoconjunctivitis for the reduction in the size and number of papillae by fifty percent after two weeks, and there is no recurrence of the papillae for three months. Additional quantitative measurements included were resolution of punctate epithelial erosions.

Keywords: Vernal Keratoconjunctivitis, Supratarsal injection, Triamcinolone acetonide.

Submitted on ----- Revised on ----- Accepted on -----

INTRODUCTION

Vernal keratoconjunctivitis (VKC) is a chronic, severe form of allergic eye disease usually affecting children and young adults. Clinically, it is a common bilateral atopic illness with papillary, limbal, and mixed types of limbal papillae (Horner Tranta dots) (Kaur K, 2024). The episodes have seasonal recurrences and are frequently periodic (Vichyanond & Kosrirukvongs, 2013). The development of VKC is significantly influenced by environmental factors, which are more common in warm, dry, and windy regions and deteriorate in severity due to air pollution and Asian dust storms (Thong, 2017; Zicari *et al.*, 2019).

An estimated 3-6% of the global population experiences allergic conjunctivitis alone, while up to 30% of children experience it either by itself or in conjunction with allergic rhinitis (Leonardi *et al.*, 2015). While it is also common in the Mediterranean region, North America, and Australia, VKC is most common in Asia, Central and West Africa, and South America.

Mild cases of VKC improve generally with supportive therapy, while severe cases can experience relapses and may follow a prolonged course which can ultimately handicap the patient visually. A papillary reaction in the upper tarsal conjunctiva and throughout the limbus is one of the clinical symptoms of VKC (Addis & Jeng, 2018). The intense itching, stringy mucoid discharge along with lacrimation may lead to severe vision debilitating complications. Immunoglobulin E-mediated pathogenicity

is the predominant mechanism; non-immunoglobulin E and certain nonspecific hypersensitivity pathways may exist. Eosinophils and CD4 T cells are the two main cell types involved (Singhal *et al.*, 2019).

Even though more focused medications are now possible due to improved understanding of the pathophysiology of VKC, managing these individuals can still be extremely difficult and lead to problems (Addis & Jeng, 2018). The treatment of VKC involves the use of different types of medications. These aim to control symptoms, reduce inflammation and prevent long term complications. A combination of pharmacologic and supportive approaches is needed. Raised intraocular pressure, formation of cataract, occurrence of infectious keratitis including herpes simplex keratitis are some potential complications associated with prolonged use of topical steroids. Topical cyclosporine or tacrolimus ointments are used as steroid sparing regimes for chronic cases (Irfan S, 2015).

The main goal of treatment is to reduce the size and number of the papillae present on the tarsal conjunctiva which cannot be achieved only with topical eye drops. The low retention rate of the steroid eye drops along with noncompliance of the patients due to multiple and frequent daily doses makes it even more difficult. Other modalities of treatment have thus been introduced which include topical tacrolimus ointment and supratarsal steroid injections. Pharmacological treatment for individuals with a history of VKC should be scheduled in advance and either begin in the spring or continue throughout the year,

*Corresponding author: e-mail: sultan.maham2010@outlook.com

contingent upon the duration of symptoms and the amount of allergen exposure (Mehta *et al.*, 2022).

In patients with more chronic VKC, acute exacerbations, or when the cornea is affected, topical corticosteroid eye drops should be given as brief, pulsed therapy to relieve symptoms (Leonardi *et al.*, 2019). By reversing arterial dilatation and permeability, corticosteroids exhibit their anti-inflammatory actions by preventing macrophage and leukocyte migration to the afflicted location. Reduced erythema, pruritus, and edema are the results of these actions (Sidhu & Preuss, 2024). Triamcinolone belongs to the corticosteroid drug class and is a glucocorticoid. Since 1996, very few reports have documented the effectiveness of supratarsal corticosteroid injections for the management of severe VKC. By lowering local inflammation, a supratarsal steroid injection relieves symptoms initially. Triamcinolone is a synthetic glucocorticoid that exerts its anti-inflammatory and immunosuppressive effects by inhibiting phospholipase A2, stabilizing lysosomal membranes and preventing arachidonic acid release. It inhibits cyclooxygenase (COX) and lipoxygenase (LOX) pathways, reducing the production of prostaglandins and leukotrienes, which are the main mediators of inflammation. Furthermore, even in patients who are noncompliant, supratarsal triamcinolone injection might be devised as a temporary solution before any surgical operation (Zicari *et al.*, 2019).

Multiple researchers studied the use of supratarsal injection of triamcinolone in different forms of VKC and in different population varying from school going children to adults. Variable findings are reported regarding its effectiveness in terms of symptoms resolution and disease recurrence. (Costa *et al.*, 2017; Gul *et al.*, 2019; Saini *et al.*, 1999).

Managing VKC resistant to topical treatments remains a significant challenge to ophthalmologists due to its chronic, relapsing nature, variability in presentation, complex pathophysiology, and the long-term demands of therapy coupled with potential side effects. This study underscores the need for effective and safe alternatives, focusing on the efficacy of supratarsal triamcinolone acetonide injections. These injections aim to reduce the size and number of tarsal papillae, alleviate symptoms and improve disease control. Additionally, the study evaluates the treatment's safety profile by monitoring changes in intraocular pressure and identifying other potential adverse effects, offering a comprehensive approach to managing refractory VKC.

MATERIALS AND METHODS

Study design and setting

This randomized control trial was conducted at the Ophthalmology Department of Layton Rahmatullah Benevolent Trust (LRBT) Hospital, Karachi, Pakistan,

from August 2023 to January 2024. Approval was obtained from the hospital ethics committee (LRBT/TTEH/4406/02).

Participant enrollment

The study included patients aged 7–18 years of either gender diagnosed with bilateral vernal keratoconjunctivitis (VKC) characterized by cobblestone papillae, unresponsive to routine treatment for at least four weeks. The study excluded patients younger than seven years, those with conjunctival scarring disorders, infectious corneal ulcers, history of herpetic keratitis, contact lens users, intraocular pressure (IOP) >21 mmHg, or prior surgical excision of giant papillae.

Sample size calculation

Based on a previous study reporting an 86.73% effectiveness rate of supratarsal triamcinolone acetonide injections in VKC patients (Khan, 2015), the required sample size was estimated to be 91 patients. The calculation assumed a 95% confidence level and a 7% margin of error, performed using the Open-Epi online calculator.

Procedure

Proparacaine 0.5% eye drops were used as a local anesthetic. Patients were instructed to look downward, and the upper eyelid was gently everted. A cotton-tipped applicator soaked in 4% lidocaine was applied for one minute. A 26-gauge needle was then inserted into the supratarsal area between the conjunctiva and Müller's muscle, 1 mm above the superior tarsomedial boundary. A 0.5 mL (20 mg) dose of triamcinolone acetonide was injected into the potential space, followed by compression with a pressure pad for 2–3 minutes. After injection, all topical medications were discontinued, and patients were followed up for two weeks.

Follow-Up and assessment

Patients underwent a detailed ocular examination at presentation and during follow-ups. Visual acuity was recorded, and IOP was measured using a Goldmann applanation tonometer at each visit. The cornea was assessed for punctate epithelial erosions using fluorescein staining under a cobalt filter. The tarsal conjunctiva was visualized by everting the eyelid with a cotton-tipped applicator.

Outcomes were evaluated two weeks post-injection, focusing on the regression of cobblestone papillae, resolution of punctate epithelial erosions, and symptom relief. Patients showing at least a 50% regression in papillae were followed for three months to monitor recurrence. Three days before the injection, all topical medications except lubricants were stopped. After two weeks, a topical commercial preparation of 0.5% cyclosporine was initiated.

Outcome variables

The primary outcome was the effectiveness of the treatment, defined as a $\geq 50\%$ reduction in cobblestone papillae size and complete resolution of keratitis. Secondary outcomes included the recurrence of papillae and the incidence of complications.

STATISTICAL ANALYSIS

Data were analyzed using IBM SPSS (version 27). Qualitative variables were expressed as frequencies and percentages, while quantitative variables were presented as means \pm standard deviations. Symptom frequencies before and after treatment were compared using McNemar's chi-square test. Statistical significance was set at a two-tailed p-value < 0.05 .

RESULTS

Patients' demographic and clinical features at baseline

A total of 91 patients were studied with a mean age of 11.6 ± 3.5 years. Male proportion was 54.9%. Patients presented with symptoms of eye redness (92.3%), itching (92.3%), blurred vision (92.3%), light sensitivity (89%) and (82.4%) had swelling (table 1).

Clinical features after treatment

After treatment, 36.3% had itching, 29.7% had blurring of vision, 15.4% had eye redness, 6.6% had swelling and 3.3% had light sensitivity. Statistically significant difference was seen in frequency of all symptoms before and after treatment (table 2).

Treatment efficacy, recurrence and complications

There was a 50% reduction in the size of the papillae in half of the cases seen through direct visualization by slit lamp biomicroscopy and pre and post injection photographs. Efficacy in terms of significant decrease of papillae at 2 weeks follow-up was 69.2%. Efficacy rate was not significantly different based on age and gender (table 3). Complications were seen in terms of blepharoptosis (5.5%), skin depigmentation (5.5%), motility issue (3.3%), conjunctival scarring (6.6%) and increase in intraocular pressure (7%). fig. 1 shows frequency of complications among those who showed disappearance of papillae and who did not show. All the complications were developed among those who did not show improvement of symptoms except blepharoptosis. None of the patients developed papillae recurrence during the next three months. Pre and post treatment results are shown for a patient in fig. 1 on 1st day and 2nd week visit respectively.

DISCUSSION

VKC is a severe type of allergic eye disease (ACD) that is known for its recurrence soon after therapy is stopped. Managing patients with VKC is still challenging as some of the patients may develop a recalcitrant disease that does

not respond to the traditional topical treatment. Limited treatment modalities are available for such patients.

Supratarsal triamcinolone injection presents an effective therapeutic choice that offers rapid response and improvement with minimal side effects. The need for systemic immunosuppression can also be potentially avoided by prompt diagnosis and appropriate treatment. This treatment is also recommended for patients who struggle with adherence to topical therapy due to high medications costs, difficulty in administrating the drops or due to absence of a reliable caregiver.

Cornea specialists largely concur that preventing complications and vision loss early in the disease's course requires strong management (Williams & Sheppard, 2005) (16). These resistant eyes inevitably experience irreversible ocular morbidity and blindness because of treatment-related or disease-related consequences (Saini *et al.*, 1999) (17). Even with the most aggressive medical intervention, such as topical antihistamines, tear substitutes, non-steroidal anti-inflammatory drugs, mast cell stabilizers, and corticosteroids, some patients still have poor disease control (Tariq, 2024). For the treatment of recalcitrant VKC, a safe and effective treatment approach is hence needed. Therefore, we investigated the effective use of supratarsal injection in the treatment of VKC.

Itching is the most common symptom, and bouts are frequently recurrent, typically perennial at first, and eventually develop into chronic conditions (Kaur K, 2024). In this study, almost all the patients (92.3%) presented with symptoms of itching, eye redness and blurred vision. These symptoms arise from the establishment of numerous papillae in the upper tarsal conjunctiva. In line with our study, signs of itching and rubbing were seen in all of patients in a study of epidemiology of VKC among school going children in Egypt (Ahmed *et al.*, 2019). Symptoms of Keratitis (100%) and cobblestone papillae (88.2%) were seen in another similar study (Costa *et al.*, 2017). Symptom of red eye among VKC was reported in all of patients in an Irish study (21). Studies also reported symptoms and signs of hyperemia (73.3%), follicles (60%), photophobia (46.7%), discharge (46.7%) burning (80%), Shield Ulcer (47%) and Tantras dots (52.9%) in VKC patients (Costa *et al.*, 2017; McSwiney *et al.*, 2019). In tropical and subtropical climates, seasonal change can be perennial or chronic, resulting in differences in clinical signs and symptoms between studies (Kumar, 2009).

This study showed the dramatic impact of the treatment as symptoms disappeared and disease was controlled after receiving treatment for 2 weeks. After treatment, 36.3% had itching, 15.4% had eye redness, 6.6% had swelling, 3.3% had light sensitivity and 29.7% had blurring of vision. 7% of cases in our study showed a rise in the intraocular pressure of at least 25% of baseline value two weeks after the injection, these patients were followed up for the next two weeks.

Table 1: Descriptive statistics for patients' demographics and presenting features.

Variables	Frequency	Percentage%
Age groups		
<10 years	25	27.4
≥10 years	66	72.5
Gender		
Male	50	54.9
Female	41	45.1
Presenting symptoms		
Itching	84	92.3
Eye redness	84	92.3
Blurred vision	84	92.3
Light sensitivity	81	89.1
Swelling	75	82.4

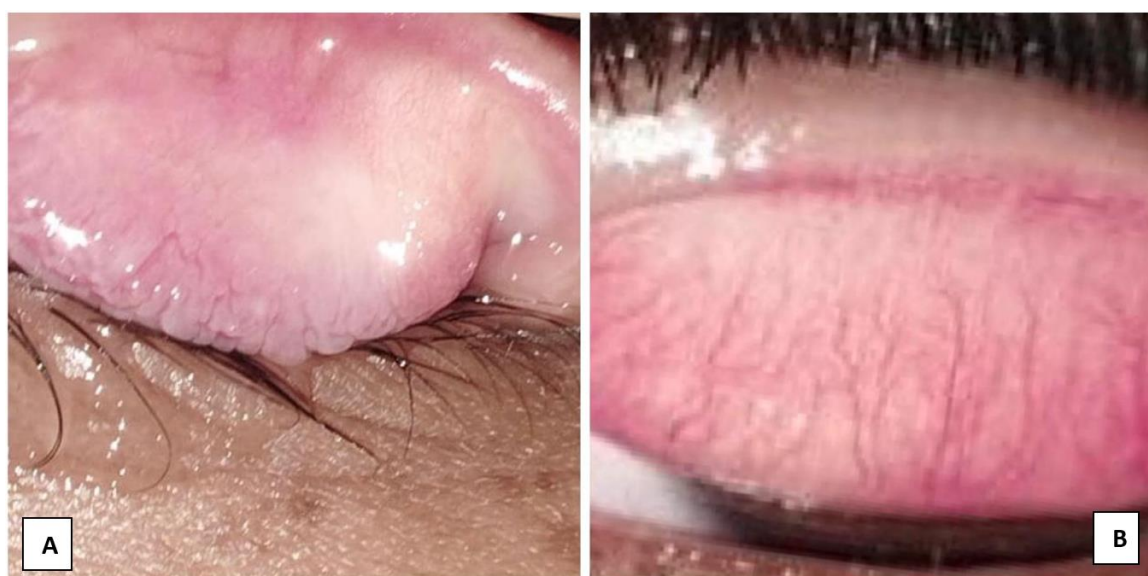

Fig. 1: Efficacy of supratarsal triamcinolone injection after 2 weeks on the upper tarsal conjunctiva. A shows inflammation of the upper tarsal conjunctiva and presence of giant papillae (largest measuring ~6mm). B shows significant resolution after treatment at two weeks follow up (largest measuring ~3mm).

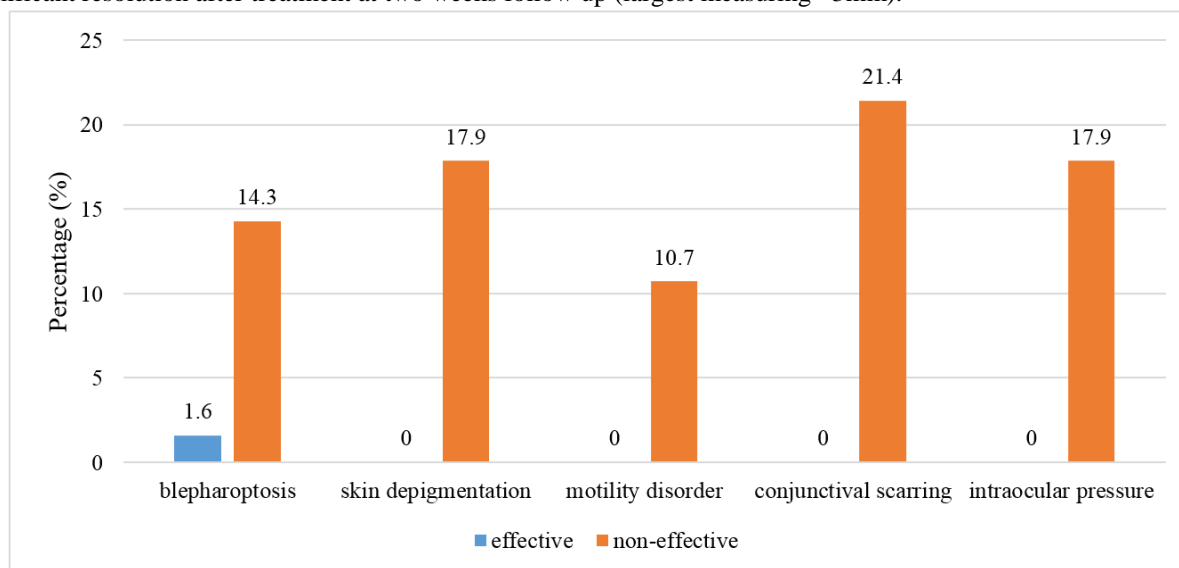


Fig. 2: Comparison of complications among patients.

Table 2: Pre and post treatment comparison of symptoms

Before intervention		After intervention		p-value
Symptoms	Groups	Yes n (%)	No n (%)	
Itching	Yes	29(31.9)	55(60.4)	<0.001
	No	4(4.4)	3(3.3)	
Eye redness	Yes	13(14.3)	71(78)	<0.001
	No	1(1.1)	6(6.6)	
Swelling	Yes	4(4.4)	71(78)	<0.001
	No	2(2.2)	14(15.4)	
Light sensitivity	Yes	3(3.3)	78(85.7)	<0.001
	No	0(0)	10(10.1)	
Blurred vision	Yes	23(25.3)	61(67)	<0.001
	No	4(4.4)	3(3.3)	

Table 3: Summary of efficacy results w.r.t age and gender

Variables	Efficacy		p-value
	Yes n(%)	No n(%)	
Age			0.240
<10 years	15(23.8)	10(35.7)	
≥10 years	48(76.2)	18(64.28)	
Gender			0.400
Male	36 (57.1)	14(50)	
Female	27 (42.9)	14(50)	

Those patients who had persistently raised intraocular pressure were started with combination therapy of pressure lowering drugs and were followed for response. At the end of three months two patients had poor response to treatment and were referred for glaucoma evaluation. There was complete resolution of punctate epithelial erosions despite the use of steroid injection as the treatment was targeted towards eliminating the main culprit.

Aslam *et al.* looked at the effectiveness of triamcinolone injections in cases of severe VKC. Twenty percent of patients showed resolution of their shield ulcers one to three weeks after therapy started (Aslam *et al.*, 2017). Studying the efficacious use of supratarsal injection of triamcinolone revealed that 97% of patients having big papillae and active shield ulcers improved significantly following therapy (Anand *et al.*, 2017). When Costa AX examined the effectiveness in children, it was found that there was a considerable improvement in symptoms and signs, including a complete cure of lid edema and conjunctival chemosis, a significant fall in pannus and keratitis, and a reduction in the size of giant papillae (Costa *et al.*, 2017). A supratarsal injection of corticosteroids relieves symptoms initially by reducing inflammation on a local level. Depot steroid injections in the lesion prevent systemic anti-inflammatory activity and remission of inflammation at another site in the body by not significantly raising blood cortisol levels (Gul *et al.*, 2019).

In the present study, 69.2% of the patients had a greater than fifty percent decrease in the size and appearance of cobblestone papillae at the 2-week follow-up. Another

Pakistani study reported that treatment with supratarsal injection of triamcinolone was effective in all their patients (Amin *et al.*, 2021). According to research by Costa AX *et al.* (Costa *et al.*, 2017), the acute crisis was effectively managed, and all symptoms and signs subsided over an average of 3.6 months. Similarly, supratarsal triamcinolone injection was found to be 100% efficacious in severe cases of VKC that were unresponsive to topical medicines by McSwiney TJ *et al.* in their investigation on 25 patients; however, excessive asymmetry in the cases was not addressed (McSwiney *et al.*, 2019).

The present study found no recurrence of the papillae for three months. A case series of three young boys having Grossly Asymmetrical Refractory VKC also showed no recurrence till one year when treated with Supratarsal Triamcinolone Injection and Bandage Contact Lens (27). In contrast to our study, early recurrence of signs and symptoms was seen in 10.3% patients in a study of Gul N *et al.* (Gul *et al.*, 2019). An and S reported that recurrence was seen in 20-30% patients after 3 months (24). Costa AX reported that 11 out of 17 patients experienced recurrence of ocular allergy but in milder form (Costa *et al.*, 2017). The findings of recurrence in VKC cases when treated with modality of supratarsal injection are variable in available literature. The variability could occur in nature because of different genetics of patients and the pattern of self-care behavior.

Usually, VKC resolves without complications unless it is over treated, treatment should be conservative, and iatrogenic side effects should be avoided. Any new

therapeutic intervention should be designed with these considerations in mind. In this study, we observed some complications of supratarsal triamcinolone injection. Out of 27 patients, only one had intraocular pressure, which increased from 11 to 16 mmHg after 4 days of the triamcinolone injection, according to Costa AX *et al* (Costa *et al.*, 2017). No intraoperative and postoperative complications were seen in a study of Gul N *et al* (Gul *et al.*, 2019). Complications in terms of intraocular pressure rise requiring treatment, development of lenticular opacity, or ptosis after supratarsal injection of triamcinolone were also reported by McSwiney TJ *et al* (McSwiney *et al.*, 2019).

The present study was performed in a single institution in Karachi with a limited sample size. Moreover, we did not include any control group in this study. Thus, a future study may be performed to fill the gap of current study and validate our findings.

CONCLUSION

In conclusion of our study, we can safely say that supratarsal triamcinolone injection is effective in patients with recalcitrant vernal keratoconjunctivitis, leading to at least 50% reduction in size of giant papillae, complete resolution of punctate epithelial erosions and significant decrease in the severity of symptoms. Timely treating the disease not only has a significant impact on the mental and physical wellbeing of the patient but can also decrease the financial burden caused by long-term use of multiple medications.

REFERENCES

- Addis H and Jeng BH (2018). Vernal keratoconjunctivitis. *Clin. Ophthalmol.*, **12**: 119-123.
- Ahmed SM, Ahmed KEOS, El Morsy OA and Soliman SS (2019). Epidemiology of Vernal Keratoconjunctivitis (VKC) among children aged (12-15) years-Menofia Governorate, Egypt. *Delta Journal of Ophthalmology*, **20**(1): 1-6.
- Amin M, Kakar AB, Tajwidi C, Farooq N, Ghauri HWA, and Zaman A (2021). Efficacy of Supratarsal Triamcinolone Injection versus Dexamethasone in Recalcitrant Vernal Keratoconjunctivitis. *Pak J Med Health Sci.*, pp.-----?
- Anand S, Varma S and Sinha VB (2017). A comparative study on uses of supratarsal triamcinolone injection, topical steroids and cyclosporine in cases of refractory vernal keratoconjunctivitis. *Journal of Evolution of Medical and Dental Sciences*, **6**(14): 1129-1133.
- Aslam S, Arshad M and Khizar M (2017). Efficacy of Supratarsal Injection of Triamcinolone Acetonide (Corticosteroid) for treating severe Vernal Keratoconjunctivitis (VKC) refractory to all Conventional Therapy. *Pak. J. Med. Health Sci.*, **11**: 656-658.
- Costa AXD, Gomes JAP, Marculino LGC, Liendo VL, Barreiro TP and Santos MSD (2017). Supratarsal injection of triamcinolone for severe vernal keratoconjunctivitis in children. *Arq Bras Oftalmol*, **80**(3): 186-188.
- Gul N, Israr M, Farhan M, Khan MN, Khattak M and Qadir A (2019). Supratarsal injection of triamcinolone acetate for the treatment of severe vernal keratoconjunctivitis. *Journal of Postgraduate Medical Institute*, **33**(1): pp.-----?
- Irfan S, Ahmed A and Rasheed F (2015). To assess the efficacy and safety of tacrolimus skin cream, 0.03% in moderate to severe vernal keratoconjunctivitis. *Pakistan Journal of Ophthalmology*, **31**(1):
- Kaur KGB (2024). Vernal keratoconjunctivitis. StatPearls Publishing. Retrieved 1 June, 2024 from <https://www.ncbi.nlm.nih.gov/books/NBK576433/>
- Khan SA (2015). Effectiveness of Supratarsal Triamcinolone Injection in Patients with Vernal Keratoconjunctivitis. *Pakistan Journal of Ophthalmology*, **31**(2): pp.-----?
- Kumar S (2009). Vernal keratoconjunctivitis: a major review. *Acta Ophthalmol*, **87**(2): 133-147.
- Leonardi A, Castegnaro A, Valerio AL and Lazzarini D (2015). Epidemiology of allergic conjunctivitis: Clinical appearance and treatment patterns in a population-based study. *Curr Opin Allergy Clin Immunol*, **15**(5), 482-488.
- Leonard A, Silva D, Perez Formigo D, Bozkurt B, Sharma V, Allegri P, Rondon C, Calder V, Ryan D, Kowalski ML, Delgado L, Doan S and Fauquert JL (2019). Management of ocular allergy. *Allergy*, **74**(9): 1611-1630.
- McSwiney TJ, Power B, Murphy CC, Brosnahan D and Power W (2019). Safety and Efficacy of Supratarsal Triamcinolone for Treatment of Vernal Keratoconjunctivitis in Ireland. *Cornea*, **38**(8): 955-958.
- Mehta JS, Chen WL, Cheng ACK, Cung LX, Dualan IJ, Kekunnaya R, Khaliddin N, Kim TI, Lam DK, Leo SW, Manurung F, Tesavibul N and Bremond-Gignac D (2022). Diagnosis, Management and Treatment of Vernal Keratoconjunctivitis in Asia: Recommendations From the Management of Vernal Keratoconjunctivitis in Asia Expert Working Group. *Front Med (Lausanne)*, **9**: 882240.
- Saini JS, Gupta A, Pandey SK, Gupta V and Gupta P (1999). Efficacy of supratarsal dexamethasone versus triamcinolone injection in recalcitrant vernal keratoconjunctivitis. *Acta Ophthalmol Scand*, **77**(5): 515-518.
- Sidhu G and Preuss CV (2024). Triamcinolone. In StatPearls. StatPearls Publishing Copyright © 2024, StatPearls Publishing LLC.
- Singhal D, Sahay P, Maharana PK, Raj N, Sharma N and Titiyal JS (2019). Vernal Keratoconjunctivitis. *Surv Ophthalmol*, **64**(3): 289-311.

- Tariq F (2024). Allergic Conjunctivitis: Review of Current Types, Treatments, and Trends. *Life (Basel)*, **14**(6): <https://doi.org/10.3390/life14060650>
- Thong BY (2017). Allergic conjunctivitis in Asia. *Asia Pac Allergy*, **7**(2): 57-64.
- Vichyanond P and Kosirukvongs P (2013). Use of cyclosporine A and tacrolimus in treatment of vernal keratoconjunctivitis. *Curr. Allergy Asthma Rep.*, **13**(3): 308-314.
- Williams PB and Sheppard JD Jr (2005). Omalizumab: a future innovation for treatment of severe ocular allergy? *Expert Opin Biol Ther.*, **5**(12): 1603-1609.
- Zicari AM, Capata G, Nebbioso M, De Castro G, Midulla F, Leonardi L, Loffredo L, Spalice A, Perri L and Duse M (2019). Vernal Keratoconjunctivitis: An update focused on clinical grading system. *Ital J Pediatr.*, **45**(1): 64.

s